Toxicity profile of the aqueous methanol stem bark extract of *Erythrina senegalensis* DC. (Fabaceae) in rodents

Mathias Sylvester Nefai*[1], Ibrahim Yusuf Alkali[2] , Chinenye Jane Ugwah-Oguejiofor[2], Mshelia Halilu Emmanuel[1,3], Aminu Ahmed Biambo[4], Mansur Lawal[1], Aliyu Hamidu Ahmed[1]

[1]Department of Pharmacognosy and Ethnomedicine, Usmanu Danfodiyo University, Sokoto
[2]Department of Pharmacology and Toxicology, Usmanu Danfodiyo University, Sokoto
[3]Faculty of Pharmacy, Cyprus International University, Haspolat/Nicosia, Mersin, Turkey
[4]Department of Clinical Pharmacy and Pharmacy Practice, Usmanu Danfodiyo University, Sokoto

Submitted: 4th June, 2025; Accepted: 21st June, 2025; Published online: 30th June, 2025
DOI: https://doi.org/10.54117/jcbr.v5i3.5
**Corresponding Author: Mathias Sylvester Nefai; sylver_74ng@yoahoo.com; +2348039737900*

Abstract

Erythrina senegalensis DC. (Fabaceae) is widely used in African traditional medicine, particularly the stem bark, which is employed in treating ailments such as malaria, jaundice, gastrointestinal disorders, and inflammation. Its extensive folkloric use underscores the need for rigorous toxicological validation. This study evaluated the acute and sub-chronic oral toxicity of the crude aqueous methanol extract of the stem bark (CAMEES) in Wistar rats. Acute toxicity was assessed using Lorke's method, while sub-chronic toxicity followed the Organization for Economic Co-operation and Development (OECD) Guideline 407. In the 28-day sub-chronic study, fifty-six rats (28 males and 28 females) were divided into four groups (n = 7/sex/group) and administered 0 (control), 250, 500, or 1000 mg/kg/day of CAMEES orally. Parameters evaluated included body weight, food intake, haematology, serum biochemistry, organ weight, and histopathology. No mortality or observable clinical toxicity was recorded in the acute phase, and the oral LD_{50} was estimated to exceed 5000 mg/kg. Sub-chronic administration did not cause significant alterations in body weight or food consumption. However, significant increases in serum glucose (8.4 ± 0.9 vs. 7.2 ± 1.8 mmol/L; P = 0.043), total cholesterol (385.6 ± 68.2 vs. 305.1 ± 6.2 mmol/L; P = 0.039), and albumin (4.9 ± 0.2 vs. 3.7 ± 0.4 g/L; P = 0.046) were observed at specific doses. Mild sex-related variations in lymphocyte and platelet counts were also noted ($P < 0.05$). Histological examination revealed no lesions in major organs. Overall, CAMEES exhibited a favorable safety profile, supporting its

continued investigation for therapeutic applications.

Keywords: Toxicity, Wistar rats, biochemical parameters, *E. senegalensis*

Introduction

The world is increasingly turning to medicinal plants for primary healthcare, especially in developing nations where traditional medicine plays a crucial role. In Africa, herbal remedies are commonly prepared and administered by traditional healers, often without formal scientific validation of their efficacy or safety (Fokunang *et al*., 2011; Wang *et al*., 2021). While some plant-based treatments have been pharmacologically evaluated, many still lack comprehensive toxicological assessments, leading to the widespread but incorrect belief that natural products are inherently safe (Fennell *et al*., 2004). However, this assumption has been challenged by numerous studies demonstrating toxicity in traditionally used plants. For instance, *Lantana camara* and *Aphania senegalensis* have been linked to hepatotoxicity (Atsamo *et al*., 2011), while *Herniaria cinerea* has been associated with gastrointestinal disturbances(Chen *et al*., 2021). The prolonged use of *Ginkgo biloba* may result in adverse hematological outcomes such as spontaneous bleeding and subdural hematomas (Bent *et al*., 2005), and the alkaloid-rich *Ephedra* species are known to induce serious cardiovascular and central nervous system effects (Brown *et al*., 2012). These examples highlight the pressing need for rigorous toxicological evaluation of medicinal plants, particularly in Africa where many are still in widespread use despite incomplete safety profiles (Moreira *et al*., 2014).

Erythrina senegalensis DC. (Fabaceae), commonly known as the coral tree or “Minjirya” in Hausa, is a leguminous plant native to West Africa, notably found in Nigeria, Senegal, and Cameroon. It holds significant traditional medicinal value and is frequently used to manage ailments such as malaria, jaundice, pneumonia, gastrointestinal disorders, rheumatism, and infertility (Fofana *et al*., 2022; Gill, 1992). The stem bark is especially popular in ethnomedicine, typically administered as a decoction for oral or topical use (Saidu *et al*., 2000).

Phytochemical investigations have identified numerous bioactive constituents in *E. senegalensis*, including alkaloids, flavonoids, tannins, glycosides, and prenylated isoflavones (Doughari, 2010, 2020; Lee *et*

al., 2009). Among these, Erythrina alkaloids such as erysodine and erythroidine are of pharmacological interest due to their neuromuscular blocking effects, which confer potential therapeutic applications as muscle relaxants but also imply neurotoxic risks at high doses or prolonged exposure (Doughari, 2010; Lee *et al*., 2009). Earlier pharmacological studies have demonstrated the plant's antimalarial, antioxidant, and anti-inflammatory properties (Atsamo *et al*., 2011; Tyohemba *et al*., 2019). Aqueous stem bark extracts have been reported to be non-toxic at doses up to 5000 mg/kg in acute toxicity models and have shown hepatoprotective effects against cadmium-induced damage (Tyohemba *et al.*, 2019). Nevertheless, chronic administration has been associated with adverse histopathological changes such as hepatocellular degeneration, myocardial hemorrhage, and tubular necrosis ((Atsamo *et al*., 2011; Okokon *et al*., 2022).

It is important to note that toxicity studies on various parts of plants have raised some red flags. For example, when researchers looked at methanolic leaf extracts from *E. senegalensis*, they found significant dose-dependent cytotoxicity in brine shrimp lethality tests, along with some concerning changes to liver architecture in sub-acute oral toxicity studies (Ukwueze *et al*., 2024; Obidah *et al*., 2014). In a similar vein, the root extract showed abortifacient effects and increased uterine contractility in animal models, hinting at potential reproductive toxicity (Tchacondo *et al*., 2011). These results really highlight the need for part-specific toxicological evaluations, as the safety profile can vary quite a bit depending on which part of the plant is used, how it is extracted, and the dosage involved.

Given the widespread use of *E. senegalensis* in traditional medicine and the contradictory safety data from various studies, this investigation was designed to thoroughly assess the acute and sub-chronic toxicity profile of the aqueous methanol extract of the stem bark in Wistar rats. Comprehensive haematological, biochemical, and histopathological evaluations were conducted in accordance with standardized protocols to generate updated and reliable toxicological information that could inform safe traditional or integrative medical use.

Materials and methods

Plant collection and identification

The stem bark of E. senegalensis was collected in the Tureta Local Government Area of Sokoto State Nigeria in September 2021. The plant was identified and

authenticated at the herbarium unit of the Department of Pharmacognosy and Ethnopharmacy, Faculty of Pharmaceutical Sciences, Usmanu Danfodiyo University, Sokoto, following compilations of Hausa plant names (Blench *et al.*, 2007) and vernacular names of Nigerian plants (Gbile, 2017). A voucher number PCG/UDUS/Faba /0027 was referenced and assigned.

Plant preparation

The stem bark of E. senegalensis was air-dried then pulverized into moderately coarse powder and stored in a moisture-free container for further use (WHO, 2011).

Extraction of plant material

The *E. senegalensis* stem-bark powder (1kg) was defatted in n-hexane and subsequently extracted with 70% methanol (v/v) by maceration for 7 days. An aqueous methanol volume of 1mL for 4g of the powdered plant (ratio 4:1 w/v) was used. The extract was concentrated *in-vacuo* at reduced pressure and maintained at 45°C using a rotary evaporator. The extract was partially freeze-dried to yield crude aqueous methanol extract of *E. senegalensis* (CAMEES) which was stored in a desiccator until required for further use.

The percentage (%) yield of CAMEES was estimated using the formula:

$$\% \text{ yield} = \frac{Amount\ of\ CAMEES}{\text{Amount of Powdered } E.\ senegalensis} \times 100\%$$

Phytochemical screening

The qualitative phytochemical screening of CAMEES was conducted using the methods described in various literature (Evans, 2009; Shah & Seth, 2010).

Elemental analysis (X-Ray fluorescence)

The sample was crushed using Mixer/Mill (8000M) SPEX sample preparation machine for 5 minutes. The powder was transferred into a pellet preparation sample holder and compressed using a hydraulic press at 35 Mega Pascal. This was analyzed on XFF ZSX Primus (Rigaku). The methods described in associated literatures were followed (Ene *et al*., 2010).

Experimental animals

Adult Wistar rats of both sexes weighing between (120 g and 150 g, 80-10 weeks old) were used in this study. The animals were obtained and purchased from the animal house Ahmadu Bello University Zaria, Kaduna State Nigeria. The rats were housed under controlled conditions in the experimental animal handling facility of the

Faculty of Pharmaceutical Science, Usmanu Danfodiyo University Sokoto. The experimental animal room had a 12 hour light /12 hour dark scheduled and maintained at a temperature of 23±3°C throughout the study. Animals were fed with commercially available rat pelleted diet (livestock feed) and were allowed access to water *ad libitum* throughout the period of the experiment. The experimental protocols were approved by the Institutional Animal Care and Use Committee, Department of Pharmacology and Toxicology, Usmanu Danfodiyo University Sokoto.

Acute toxicity study

Oral acute toxicity was studied using the method described by Lorke (1983). The study was conducted in two phases. In the first phase, nine animals of both sexes were randomly distributed into three groups of three animals each. Groups 1, 2 and 3 received 10, 100, and 1000mg/kg of the extract respectively, and were observed for 24 hours for any signs of toxicity and mortality. In the second phase four animals were used, one animal per group, and were administered with 1200, 1600, 2900, and 5000mg/kg doses of CAMEES respectively. The LD_{50} was determined. Extract administration was carried between 9 and 11 am.

Sub-chronic toxicity study (OECD 407)

Twenty-eight male and an equal number of female albino rats that previously fasted for 24 hours were divided into four groups each containing seven animals respectively. Each group received treatment as follows:

Group1 (control): received 10ml/kg/day of distilled water

Group 2: received 250 mg/kg of CAMEES

Group 3: received 500 mg/kg of CAMEES

Group 4: received 1000 mg/kg of CAMEES

All administration was done orally once daily for 28 days. The rats had access to food and water throughout the period of the experiment. Animals were observed daily for general symptoms of toxicity and mortality. The weight of the animals was taken every week.

On the 29th day, the animals were sacrificed under light Di-ethyl Ether (DEE) anaesthesia. Blood samples were collected by cardiac puncture for biochemical and haematological analysis.

Biochemical parameters analysis

After a 28-day treatment, blood samples from Wistar rats were collected for biochemical analysis at the Usmanu Danfodiyo University Teaching Hospital (UDUTH), Sokoto

Nigeria. The samples were collected into tubes containing EDTA for hematological studies and without anticoagulant for serum separation. The serum was separated and stored at -20°C. Biochemical parameters were determined using an automated analyzer (semi-auto chemistry analyzer DS-300 Dachi Biotec., Taiwan) and standard diagnostic kits. The tests assessed liver function markers (ALT and AST), kidney function markers (BUN and Serum electrolytes including Na^+, K^+, and chloride Cl^-), lipid profile (HDL, LDL and triglyceride), and serum protein levels (total protein and albumin). All assays were carried out in triplicate to ensure accuracy. The data were statistically analyzed to determine any significant changes due to the administration of CAMEES and compared to the control group to assess potential toxicity or adverse effects.

Haematological analysis

A portion of the collected blood stored in the EDTA tubes was used to carry out the haematological analysis in the Department of Haematology, UDUTH. The study used an automated haematology analyzer (Hematology Analyzer Mindray BC-20, China) to assess the potential effects of CAMEES on the blood profile of the animals. Key hematological indices included Red Blood Cell (RBC) count, hemoglobin concentration (Hb), Hematocrit (HCT), mean corpuscular volume (MCV), mean corpuscular hemoglobin (MCH), mean corpuscular hemoglobin concentration (MCHC), white blood cell (WBC) count, platelet count, and red cell distribution width (RDW). The analysis provided critical information on the effects of CAMEES on the blood components of the treated animals, comparing them to the control group to detect any significant alterations.

Histological analysis

The fixed livers and kidney tissues were processed in 70%, 80%, 90%, and absolute alcohol following standard procedures. They were cut at 5 µm (Surgcare microtome, model 335A, USA) and dewaxed for staining with hematoxylin and eosin (H&E). An Olympus microscope equipped with a digital camera for photomicrographs was used to examine the tissues at x10 and x40 objectives (Diallo *et al.*, 2020).

Statistical analysis

All results are expressed as the mean ±S.E.M. Difference between groups were determined by one-way analysis of variance (ANOVA) using statistical package for social sciences (SPSS, version 20.0) software for windows.

Post hoctest for intergroup was applied, and significance was considered at P<0.05.

Results

Extraction and qualitative phytochemical screening

The CAMEES was chocolate brown-coloured powder and weighed 56.0 g with a percentage yield of 5.6%. The phytochemical screening revealed the presence of both primary and secondary metabolites of carbohydrates, proteins and amino acids, tannins, saponins, alkaloids, glycosides, flavonoids, steroids, volatile oils and anthraquinones.

Elemental analysis

The analysis revealed the presence of some heavy metals and mineral elementals in the powder stem bark (Table 1).

Table1. Experimental elemental compositions (%) of *E. senegalensis* stem bark

Elements	**Experimental Values** (%)	▪**PL/RDA/TDI** (Recommended values) (%)	**References**
Mg	0.3173	0.5-0.1	(Medicine, 2006)
Al	0.6085	<0.01	(Lemus & Venezia, 2015b)
Si	3.6761	<0.1	(Jugdaohsingh, 2007)
P	0.5138	0.1-0.5	(Medicine, 2006)
S	1.1844	0.2-0.3	(Medicine, 2006)
Cl	2.9188	0.2-0.4	(He & MacGregor, 2008; Medicine, 2006)
K	26.0408	0.2-0.4, (2 g/day to 4 g/day)	(Medicine, 2006; Rafferty *et al.*, 2005)
Ca	58.5567	0.1-0.5, (1 g/day to 1.2	(Medicine, 2006; Reid *et al*., 2015)
Mn	0.3185	0.01	(Baba & Mohammed, 2021)
Fe	3.3811	0.01-0.1	(Gupta *et al*., 2022; Medicine, 2006)
Zn	0.1630	0.01-0.05	(Baba & Mohammed, 2021; Medicine, 2006)
Rb	0.0582	0.01	(Medicine, 2006)
Sr	1.4564	0.01	(Lemus & Venezia, 2015b)
W	0.8042	0.01	(Johnson *et al*., 2009; Lemus & Venezia, 2015b)

▪PL = Permissible Limit
▪RDA = Recommended Daily Allowance
▪TDI = Tolerable Daily Intake

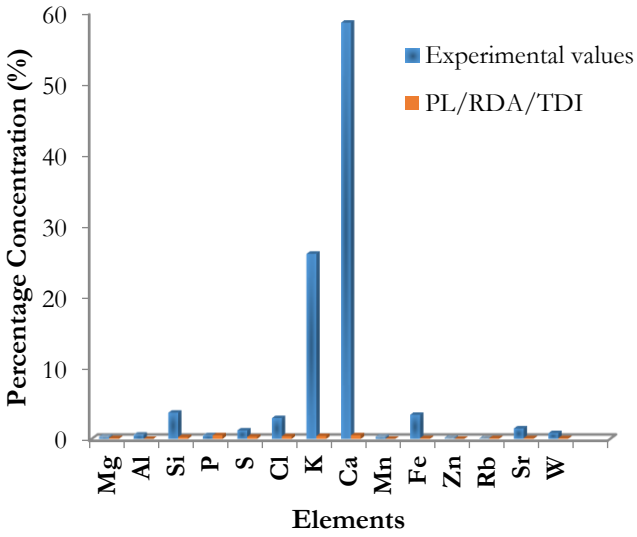

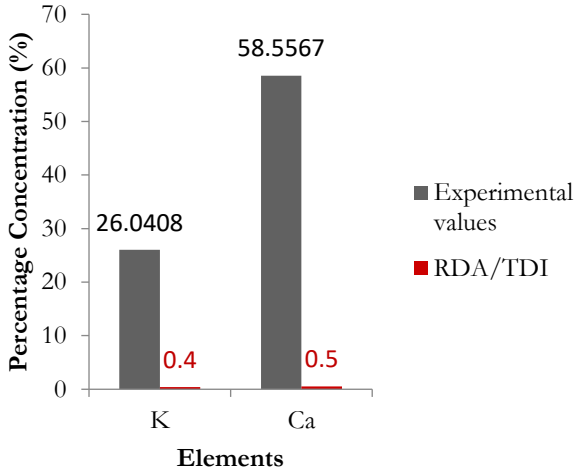

The elemental analysis reveals that several elements are present at levels much higher than recommended. While some elements like magnesium, phosphorus, and zinc are within or near safe dietary ranges, others like aluminum, potassium, calcium, manganese, iron, rubidium, strontium, and tungsten are significantly elevated.

Acute toxicity studies

After the acute administration of the extract according to Lorke's protocol, there was zero mortality observed in both the two phases. This outcome guided our conclusion that the LD50 of the extract is greater or equal to 5000 mg/kg.

Table 2. Acute toxicity study of CAMEES following Lorke's Method

Extract	Phase	Dose (mg/kg)	Death/no. Rat	Survival % (24h)	Average Time of Death (h)	Behavioural signs
CAMEES	I	10	0/3	100	No death	
		100	0/3	100	,,	
		1000	0/3	100	,,	Restlessness
	II	1600	0/1	100	,,	Restlessness,
		2900	0/1	100	,,	Restlessness. erection of pinna
CAMEES		5000	0/1	100	,,	Pupil dilation, abdominal writhing, fur erection, gasping, restlessness

CAMEES = Crude Aqueous Methanol Extract of *E. senegalensis*

Sub chronic toxicity studies

Following twenty-eight days of administration of the extract to the rats (male and female) orally, the following findings were recorded:

Effect of CAMEES on haematological parameters following twenty-eight days oral administration in rats.

The extract of *E. senegalensis* did not produces significant changes in the haematological indices as displayed below in table 2, 3 and 4.

Table 3. Effect of sub-chronic oral administration of CAMEES on haematological parameters of rats.

Haematology (WBC)

Variables		Mean (SEM) of Different Treatment (Dose)			
		Control (DW)	ES (250 mg/kg)	ES (500 mg/kg)	ES (1000 mg/kg)
WBC (10^9/L)					
	Male	13.4 (2.2)	15.6 (2.3)	13.0 (2.4)	12.6 (2.7)
	Female	9.8 (2.8)	7.4 (1.1)	13.0 (2.0)	12.9 (1.6)
	Overall	12.2 (1.8)	12.6 (1.9)	13.0 (1.5)	12.8 (1.3)
LYM (10^9/L)					
	Male	10.2 (1.9)	10.8 (1.5)	10.2 (2.1)	8.4 (1.8)
	Female	8.7 (2.8)	5.2 (0.4)	11.9 (2.0)	11.6 (1.5)
	Overall	9.7 (1.5)	8.8 (1.2)	10.9 (1.4)	10.3 (1.2)
MID (10^9/L)					
	Male	1.7 (0.3)	1.8 (0.3)	1.4 (0.2)	1.5 (0.4)
	Female	0.8 (0.1)	1.0 (0.2)	0.9 (0.1)	1.0 (0.1)
	Overall	1.4 (0.3)	1.5 (0.2)	1.2 (0.1)	1.2 (0.2)
GRA (10^9/L)					
	Male	1.5 (0.4)	1.4 (0.2)	1.4 (0.2)	2.3 (0.7)
	Female	0.4 (0.0)	1.2 (0.6)	0.3 (0.1)	0.4 (0.1)
	Overall	1.1 (0.3)	1.4 (0.2)	0.9 (0.2)	1.1 (0.4)
LYM (%)					
	Male	76.2 (3.2)	77.0 (1.0)	77.1 (2.7)	69.8 (2.0)
	Female	86.9 (3.0)	**73.2 (6.7)** *↓	89.9 (1.8)	89.4 (1.1)
	Overall	79.8 (2.8)	75.6 (2.4)	83.0 (2.5)	81.6 (3.3)
MID (%)					
	Male	12.2 (1.2)	12.6 (0.7)	11.6 (0.9)	12.8 (0.9)
	Female	8.8 (2.1)	12.8 (1.0)	7.7 (1.3)	7.7 (0.6)
	Overall	11.1 (1.1)	12.6 (0.5)	9.8 (0.9)	9.8 (1.0)
GRA (%)					
	Male	11.6 (2.3)	10.4 (0.5)	11.3 (2.0)	18.0 (1.7)
	Female	4.3 (0.9)	14.0 (6.0)	2.5 (0.5)	2.9 (0.5)
	Overall	9.1 (1.9)	11.7 (2.1)	7.2 (1.7)	9.0 (2.6)

ES = CAMEES;DW = Distilled water; *↑significantly **higher** than control using one-way ANOVA post hoc (dunnett test) at $p < 0.05$; *↓significantly **lower** than control using one-way ANOVA post hoc (dunnett test) at $p < 0.05$; WBC = White Blood Cell; LYM = Lymphocyte; MID = MID Cells; GRA = Granulocyte.

Haematology RBC

Variables		Mean (SEM) of Different Treatment (Dose) Control (DW)	ES (250 mg/kg)	ES (500 mg/kg)	ES (1000 mg/kg)
RBC (10^{12}/L)					
	Male	6.6 (0.2)	6.9 (0.1)	6.4 (0.2)	6.6 (0.2)
	Female	6.1 (0.2)	5.3 (0.5)	6.5 (0.2)	6.5 (0.1)
	Overall	6.4 (0.1)	6.3 (0.3)	6.5 (0.1)	6.5 (0.1)
HGB (g/dl)					
	Male	12.7 (0.6)	13.0 (0.2)	12.9 (0.6)	13.0 (0.4)
	Female	13.1 (0.7)	**10.2 (1.0)** *↓	13.8 (0.5)	13.4 (0.4)
	Overall	12.8 (0.4)	12.0 (0.6)	13.3 (0.4)	13.2 (0.3)
HCT (%)					
	Male	43.8 (1.9)	40.5 (0.9)	42.0 (1.8)	44.0 (0.7)
	Female	41.4 (1.6)	36.7 (4.2)	45.7 (2.0)	44.7 (1.4)
	Overall	43.0 (1.4)	39.1 (1.6)	43.7 (1.4)	44.5 (0.8)
MCV (fL)					
	Male	66.4 (1.4)	**58.7 (0.6)** *↓	65.4 (2.1)	67.2 (2.1)
	Female	68.0 (2.4)	68.4 (3.5)	70.2 (1.7)	69.2 (1.8)
	Overall	66.9 (1.2)	62.2 (1.9)	67.6 (1.5)	68.4 (1.3)
MCH (Pg)					
	Male	19.3 (0.4)	18.9 (0.3)	20.8 (1.2)	19.7 (0.6)
	Female	21.4 (0.6)	**19.1 (0.6)** *↓	21.2 (0.4)	21.2 (0.5)
	Overall	20.0 (0.5)	19.0 (0.3)	21.0 (0.6)	20.6 (0.4)
MCHC (Pg)					
	Male	29.0 (0.4)	32.3 (0.5)	30.7 (0.7)	25.1 (3.9)
	Female	31.6 (1.2)	**28.1 (0.8)** *↓	30.2 (0.7)	30.6 (0.3)
	Overall	29.9 (0.6)	30.7 (0.8)	30.5 (0.5)	28.4 (1.7)
RDW-SD (fL)					
	Male	50.2 (1.6)	**42.8 (0.5)** *↓	47.1 (1.7)	48.7 (1.3)
	Female	47.3 (2.2)	50.7 (2.8)	49.9 (1.3)	49.4 (1.1)
	Overall	49.3 (1.3)	45.6 (1.6)	48.4 (1.1)	49.1 (0.8)
RDW-CV (%)					
	Male	15.9 (0.2)	15.7 (0.1)	**15.3 (0.1)** *↓	15.3 (0.2)
	Female	14.3 (0.2)	15.5 (0.6)	14.6 (0.2)	14.7 (0.3)
	Overall	15.4 (0.3)	15.6 (0.2)	15.0 (0.1)	14.9 (0.2)

ES = CAMEES; DW = Distilled water; *↑significantly **higher** than control using one-way ANOVA post hoc (dunnett test) at $p < 0.05$; *↓significantly **lower** than control using one-way ANOVA post hoc (dunnett test) at $p < 0.05$; RBC = Red Blood Cell; HGB = Haemoglobin; HCT = Haematocrit; MCV = Mean Cell Volume; MCH = Mean Corpuscular Haemoglobin; MCHC = Mean Corpuscular Haemoglobin Concentration; RDW-SD = Red Cell Distribution Width Standard Deviation; RDW-CV = Red Cell Distribution Width Coefficient of Variation

Haematology PLT

Variables		Mean (SEM) of Different Treatment (Dose) Control (DW)	ES (250 mg/kg)	ES (500 mg/kg)	ES (1000 mg/kg)
PLT (10^9/L)					
	Male	583.2 (153.9)	613.9 (63.9)	466.6 (60.9)	435.3 (145.2)
	Female	345.3 (185.9)	790.3 (173.2)	605.3 (62.5)	545.8 (70.9)
	Overall	503.9 (119.7)	678.0 (74.5)	530.6 (46.4)	501.6 (69.4)
MPV (fL)					
	Male	7.2 (0.2)	7.1 (0.1)	7.2 (0.2)	6.8 (0.1)
	Female	7.8 (0.2)	21.8 (15.1)	7.0 (0.2)	6.9 (0.1)
	Overall	7.4 (0.2)	12.4 (5.5)	7.1 (0.1)	6.9 (0.1)
PDW (fL)					
	Male	13.4 (0.7)	12.8 (0.3)	13.4 (0.7)	14.0 (2.0)
	Female	11.9 (3.5)	12.3 (0.2)	12.2 (0.2)	12.1 (0.2)
	Overall	12.9 (1.1)	12.6 (0.2)	12.9 (0.4)	12.9 (0.8)
PCT (%)					
	Male	0.4 (0.1)	0.4 (0.0)	0.3 (0.0)	0.4 (0.1)
	Female	0.3 (0.1)	0.5 (0.1)	0.4 (0.0)	0.4 (0.0)
	Overall	0.4 (0.1)	0.5 (0.0)	0.4 (0.0)	0.4 (0.0)
P-LCR (%)					
	Male	15.2 (1.9)	13.8 (0.8)	15.9 (1.5)	11.1 (1.0)
	Female	21.1 (1.7)	**11.9 (1.7)** *↓	**13.3 (1.2)** *↓	**13.3 (0.9)** *↓
	Overall	17.2 (1.6)	**13.1 (0.8)** *↓	14.7 (1.0)	**12.4 (0.7)** *↓

ES = CAMEES; DW = Distilled water; *↑significantly **higher** than control using one-way ANOVA post hoc (dunnett test) at $p < 0.05$; *↓significantly **lower** than control using one-way ANOVA post hoc (dunnett test) at $p < 0.05$; PLT = Platelet; MPV = Mean Platelet Volume; PDW = Platelet Distribution Width; PCT = Plateletcrit; P-LCR = Platelet to Large Cell Ratio

Effect of CAMEES on Liver function test parameters following twenty-eight days oral administration in rats.

The extract of *E. senegalensis* did not produces significant changes in the liver function indices as displayed below in table 4

Table 4. Effect of CAMEES on Liver Toxicity Markers

LFT					
		Mean (SEM) of Different Treatment (Dose)			
Variables		Control (DW)	ES (250 mg/kg)	ES (500 mg/kg)	ES (1000 mg/kg)
TB (mg/dl)					
	Male	1.9 (0.4)	1.1 (0.2)	2.0 (0.4)	1.5 (0.2)
	Female	1.1 (0.4)	0.8 (0.0)	1.0 (0.3)	0.8 (0.2)
	Overall	1.6 (0.3)	1.1 (0.2)	1.5 (0.3)	1.1 (0.2)
DB (mg/dl)					
	Male	2.2 (0.4)	1.6 (0.3)	2.5 (0.6)	2.0 (0.5)
	Female	1.4 (0.3)	2.5 (0.0)	2.1 (0.5)	3.1 (0.7)
	Overall	2.0 (0.3)	1.7 (0.3)	2.3 (0.4)	2.6 (0.5)
ALP (IU/L)					
	Male	70.4 (12.9)	116.7 (30.4)	70.7 (30.9)	71.3 (8.4)
	Female	124.3 (8.8)	62.0 (15.0)	57.0 (18.3)	53.4 (25.4)
	Overall	86.6 (12.3)	104.6 (24.7)	63.8 (17.3)	59.4 (16.9)
AST (IU/L)					
	Male	36.3 (5.0)	165.4 (28.6)	**288.7 (56.0)** *↑	165.3 (52.0)
	Female	185.3 (22.7)	363.5 (43.5)	167.0 (53.1)	213.4 (58.3)
	Overall	81.0 (23.8)	209.4 (37.1)	232.5 (41.1)	194.1 (39.5)
ALT (IU/L)					
	Male	77.3 (34.5)	190.1 (39.2)	201.3 (44.8)	184.0 (33.0)
	Female	227.0 (11.0)	262.0 (22.0)	145.7 (36.3)	213.0 (67.9)
	Overall	122.2 (33.0)	206.1 (32.0)	**175.6 (29.3)** *↑	201.4 (41.3)
TP (g/L)					
	Male	5.2 (0.2)	5.4 (0.2)	5.7 (0.2)	5.4 (0.1)
	Female	5.5 (0.5)	6.5 (0.4)	5.7 (0.2)	6.0 (0.3)
	Overall	5.3 (0.2)	5.7 (0.2)	5.7 (0.1)	5.8 (0.2)
ALB (g/L)					
	Male	3.0 (0.1)	**3.9 (0.3)** *↑	**4.3 (0.3)** *↑	3.6 (0.3)
	Female	5.4 (0.3)	5.7 (0.0)	5.5 (0.2)	5.4 (0.3)
	Overall	3.7 (0.4)	4.1 (0.3)	**4.9 (0.2)** *↑	4.7 (0.4)

ES = CAMEES; DW = Distilled water; *↑significantly **higher** than control using one-way ANOVA post hoc (dunnett test) at $p < 0.05$; *↓significantly **lower** than control using one-way ANOVA post hoc (dunnett test) at $p < 0.05$; TB = Total Bilirubin; DB = Direct Bilirubin; ALP = Alkaline Phosphate; AST = Aspartate Amino Transferase; ALT = Alanine Amino Transferase; TP = Total Protein; ALB = Albumin.

Effect of CAMEES on Renal function parameters following twenty-eight days administration in rats

There was no significant change in renal function markers after subschronic administration of the extract as displayed in table 5 below.

Table 5. Effect of CAMEES on Renal Function Markers

EUCr

		Mean (SEM) of Different Treatment (Dose)			
Variables		Control (DW)	ES (250 mg/kg)	ES (500 mg/kg)	ES (1000 mg/kg)
Sodium (mmol/L)					
	Male	146.6 (1.5)	148.6 (0.8)	146.8 (0.8)	134.4 (11.1)
	Female	151.0 (4.2)	131.6 (14.3)	147.4 (1.1)	146.9 (1.3)
	Overal l	148.1 (1.7)	143.5 (4.5)	147.1 (0.6)	141.9 (4.6)
Potassium (mmol/L)					
	Male	6.2 (0.9)	5.1 (0.4)	6.0 (0.9)	5.0 (0.6)
	Female	3.9 (0.1)	6.8 (1.0)	4.7 (0.5)	5.4 (0.8)
	Overal l	5.4 (0.7)	5.5 (0.4)	5.4 (0.6)	5.2 (0.5)
Chloride (mmol/L)					
	Male	100.7 (0.8)	101.8 (0.4)	111.6 (9.4)	100.2 (0.9)
	Female	98.2 (0.7)	101.9 (0.3)	100.4 (0.7)	98.5 (1.1)
	Overal l	99.9 (0.7)	101.8 (0.3)	106.0 (4.8)	99.1 (0.8)
Urea (mmol/L)					
	Male	12.2 (2.9)	7.6 (0.6)	13.2 (3.1)	8.7 (1.4)
	Female	10.8 (3.3)	6.0 (0.0)	11.0 (1.1)	8.2 (1.5)
	Overal l	11.8 (2.1)	7.4 (0.5)	12.0 (1.5)	8.4 (1.0)
Creatinine (mg/dl)					
	Male	0.5 (0.1)	0.4 (0.1)	0.3 (0.1)	0.5 (0.1)
	Female	0.6 (0.1)	0.7 (0.0)	0.6 (0.1)	0.6 (0.3)
	Overal l	0.5 (0.1)	0.4 (0.1)	0.4 (0.1)	0.6 (0.2)

ES = CAMEES; DW = Distilled water; *↑significantly **higher** than control using one-way ANOVA post hoc (dunnett test) at $p < 0.05$; *↓significantly **lower** than control using one-way ANOVA post hoc (dunnett test) at $p < 0.05$.

Effect of *CAMEES* on lipid profile of rats following twenty-eight days subchronic administration of the extract.

The extract at the dose of 500 mg/kg significantly ($p < 0.05$) increases the level of glucose and at the dose of 250 mg/kg it significantly ($p < 0.05$) increases the level of total cholesterol as reported below in table 6.

Table 6. Effect of CAMEESon Lipid Profile and Blood Glucose

Glucose and Lipid Profile					
		Mean (SEM) of Different Treatment (Dose)			
Variables		Control (DW)	ES (250 mg/kg)	ES (500 mg/kg)	ES (1000 mg/kg)
Glucose (mmol/L)					
	Male	4.1 (0.7)	4.2 (0.3)	**8.0 (0.3)** *↑	3.5 (0.2)
	Female	13.4 (2.5)	**5.7 (1.1)** *↓	8.6 (1.5)	**6.5 (0.9)** *↓
	Overall	7.2 (1.8)	4.8 (0.5)	8.4 (0.9)	5.3 (0.7)
TCHOL (mmol/L)					
	Male	301.6 (9.2)	293.0 (9.3)	281.3 (10.3)	341.5 (42.9)
		311.0 (7.0)	**709.5 (175.5)**	380.8 (87.2)	317.5 (22.1)
	Female		*↑		
	Overall	305.1 (6.2)	385.6 (68.2)	326.6 (40.7)	327.1 (20.6)
HDL (mmol/L)					
	Male	70.4 (12.6)	49.2 (2.9)	58.8 (7.9)	66.2 (6.5)
	Female	56.9 (6.3)	55.9 (0.0)	50.8 (5.8)	41.6 (1.3)
	Overall	65.3 (8.2)	50.0 (2.7)	54.4 (4.7)	52.5 (5.1)
TG (mmol/L)					
	Male	211.0 (0.0)	200.4 (30.4)	161.4 (36.9)	172.3 (34.8)
	Female	250.3 (75.2)	340.3 (132.7)	116.4 (7.7)	138.0 (11.0)
	Overall	240.5 (54.1)	242.4 (45.4)	138.9 (19.3)	149.4 (13.6)

ES = CAMEES; DW = Distilled water; *↑significantly **higher** than control using one-way ANOVA post hoc (dunnett test) at $p < 0.05$; *↓significantly **lower** than control using one-way ANOVA post hoc (dunnett test) at $p < 0.05$; TCHOL = Total Cholesterol; TG = Triglycerides; HDL = High-Density Lipoprotein

Effect of CAMEES on organ weight of rats following twenty-eight days sub chronic administration of the extract.

The extract at the dose of 250 mg/kg elicits significant ($p < 0.05$) increase in the lung organ weight of the animals after the twenty-eight days sub chronic administration, however there is significant ($p < 0.05$) decreased in organ weight at the dose of 500mg/kg as displayed below in table 7.

Table 7. Effect of CAMEES on Organ Weight

Organ Weight					
		Mean (SEM) of Different Treatment (Dose)			
Variables		Control (DW)	ES (250 mg/kg)	ES (500 mg/kg)	ES (1000 mg/kg)
Heart (Kg)					
	Male	0.9 (0.1)	0.8 (0.0)	**0.7 (0.0) *↓**	0.7 (0.1)
	Female	0.6 (0.0)	0.6 (0.1)	0.5 (0.0)	0.5 (0.0)
	Overall	0.8 (0.1)	0.7 (0.0)	**0.6 (0.0) *↓**	**0.6 (0.0) *↓**
Lung (Kg)					
	Male	2.1 (0.2)	2.2 (0.2)	1.9 (0.3)	1.4 (0.2)
	Female	1.0 (0.0)	**1.7 (0.3) *↑**	1.2 (0.1)	1.2 (0.1)
	Overall	1.8 (0.2)	2.1 (0.2)	1.5 (0.2)	1.3 (0.1)
Liver (Kg)					
	Male	8.6 (0.6)	10.4 (0.5)	7.3 (0.6)	8.9 (0.7)
	Female	6.3 (0.7)	7.4 (0.3)	6.1 (0.2)	6.3 (0.8)
	Overall	8.0 (0.6)	9.5 (0.6)	6.7 (0.3)	7.4 (0.7)
Kidney (Kg)					
	Male	1.6 (0.1)	1.9 (0.1)	1.4 (0.1)	1.4 (0.2)
	Female	1.1 (0.0)	1.1 (0.2)	1.0 (0.0)	1.0 (0.1)
	Overall	1.5 (0.1)	1.7 (0.1)	1.2 (0.1)	1.2 (0.1)
Pancreases (Kg)					
	Male	1.9 (0.4)	1.8 (0.2)	1.6 (0.2)	1.9 (0.2)
	Female	1.1 (0.2)	1.2 (0.2)	1.3 (0.2)	1.3 (0.1)
	Overall	1.7 (0.3)	1.7 (0.2)	1.4 (0.1)	1.5 (0.1)
Spleen (Kg)					
	Male	1.1 (0.1)	1.0 (0.1)	1.0 (0.1)	1.0 (0.1)
	Female	0.8 (0.1)	0.7 (0.0)	1.0 (0.1)	0.9 (0.1)
	Overall	1.0 (0.1)	0.9 (0.1)	1.0 (0.1)	0.9 (0.1)
Ovary (Kg)					
	Male				
	Female	0.1 (0.0)	0.3 (0.2)	0.1 (0.0)	0.2 (0.0)
	Overall	0.1 (0.0)	0.3 (0.2)	0.1 (0.0)	0.2 (0.0)
Uterus (Kg)					
	Male				
	Female	0.5 (0.0)	0.6 (0.2)	0.4 (0.0)	0.5 (0.1)
	Overall	0.5 (0.0)	0.6 (0.2)	0.4 (0.0)	0.5 (0.1)
Testes (Kg)					
	Male	5 (0.3)	5 (0.3)	4.3 (0.3)	4.3 (0.6)
	Female				

Overall	5 (0.3)	5 (0.3)	4.3 (0.3)	4.3 (0.6)

ES = CAMEES; DW = Distilled water; *↑significantly **higher** than control using one-way ANOVA post hoc (dunnett test) at $p < 0.05$; *↓significantly **lower** than control using one-way ANOVA post hoc (dunnett test) at $p < 0.05$.

Effect of CAMEES on body weight of male rats following 28 days sub-chronic administration

There is no significant alteration in body weight by the extract when compared with the distilled water treated group.

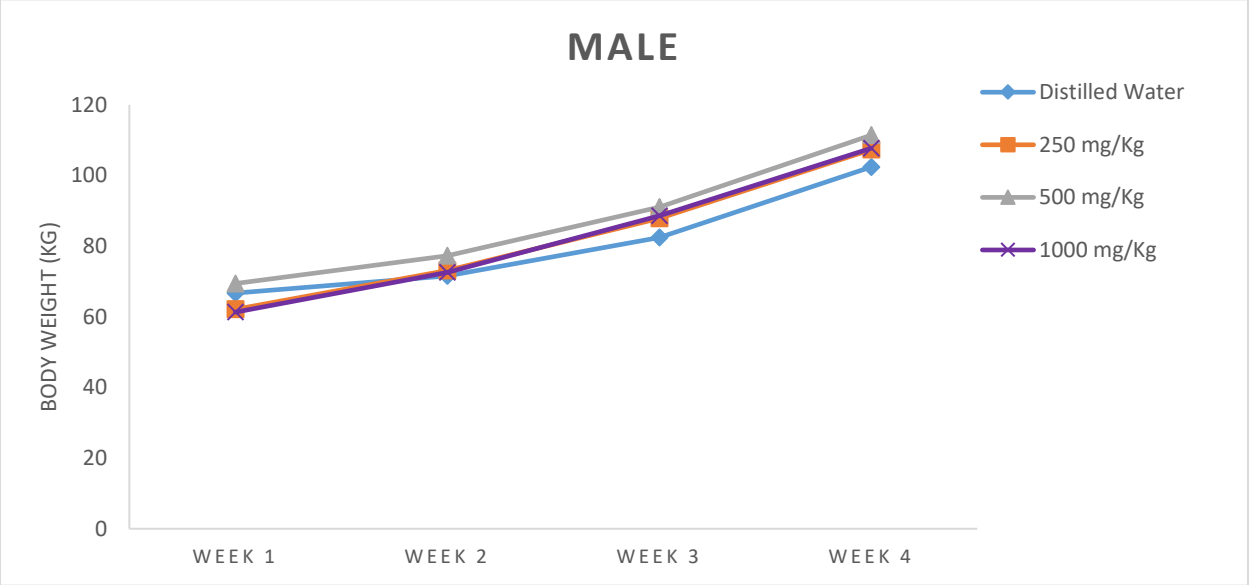

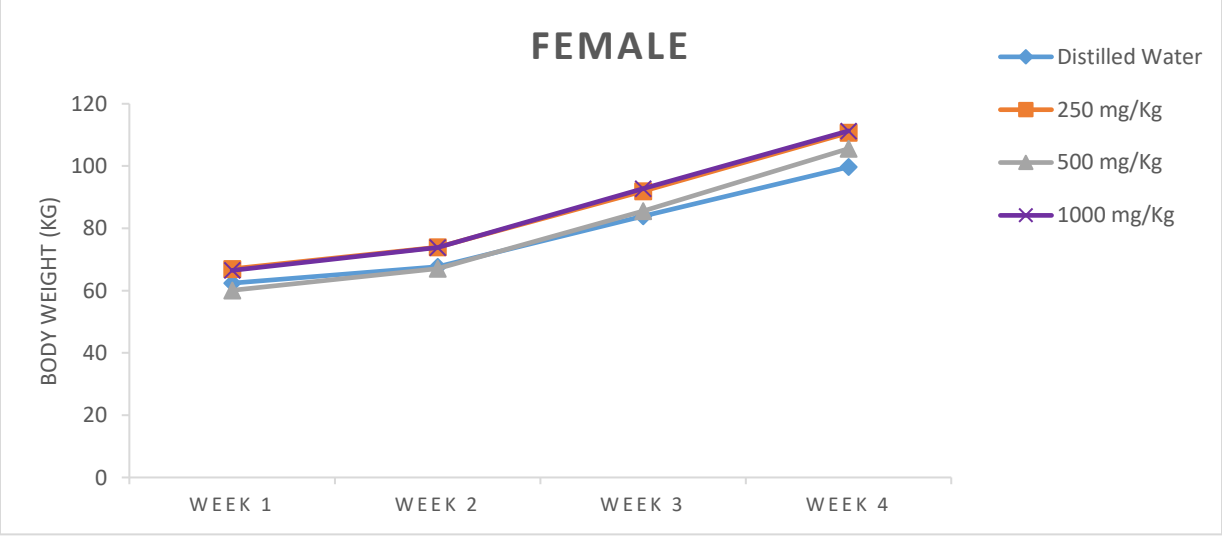

Figure 3. Effect of *E. senegalensis* on organ weight following 28 days administration of CAMEES
in female rats

Histological assessment

Histological evaluations of the vital organs in both male and female rats showed normal structure in all the treated groups when compared to the control. Representative slides of the organs treated with 1000 mg/kg of CAMEES are shown (Figure 4).

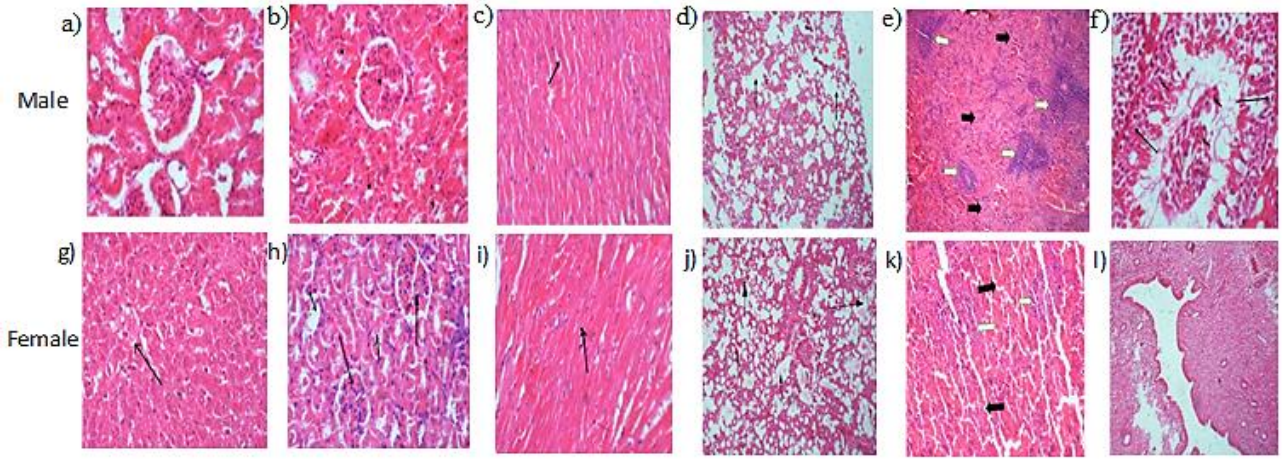

a), g) =liver; b), h) =kidney; c), i) =heart; d), j) =lungs; e), k) =spleen; f) =testis; l) =uterus

g) Liver section shows regular hepatocytes with central vein (arrow)
h) Kidney section shows regular glomeruli (long arrow) and tubules (short arrow).
c) Heart section shows regular cardiac myocytes (arrow).
d,j) Lungs section shows regular alveolar spaces.
e) k) Spleen section shows regular splenic parenchyma with white (white arrow) and red pulp (black arrow).
f) Testis section shows regular seminiferous tubules lined by sertoli cells (short arrow) with spermatogenic
cells (long arrow) at varying stage of differentiated.

Figure 4. Histology views of male and female organs treated with 1000 mg/kg of *E. senegalensis* crude methanol extract. (H & E X 100)

Discussions

Erythrina senegalensis is a staple in Traditional Medicine throughout West Africa, but it is crucial to scientifically validate its safety. This study looked into the acute and sub-chronic toxicity of its crude aqueous methanolic extract of the stem bark (CAMEES) in rodents, aiming to lay the groundwork for understanding its safety in pharmacological applications.

The elemental analysis (Table 1) showed that both essential and trace elements were present, with many exceeding safe limits. Notably, calcium (58.56%) and potassium (26.04%) were significantly higher than recommended dietary allowance (RDA) values (Heaney *et al*., 1982; Medicine, 2006). While these elements are important for our bodies, too much of them could lead to long-term health issues like nephrotoxicity, hepatotoxicity, and neurotoxicity(Ahmad *et al*., 2016; He & MacGregor, 2008; Lamy & Burckhardt, 2014). Additionally, elements like aluminum (0.61%) and tungsten (0.80%), which do not have known biological roles and can be harmful, were also found above safe levels (Lemus & Venezia, 2015a; Yokel & McNamara, 2001). The high concentrations might be linked to the plant's geographic origin or environmental conditions, suggesting a need for further ecological studies.

Acute toxicity tests (Table 2) showed that the extract did not cause any deaths or severe behavioral changes at doses up to 5000 mg/kg. Following Lorke's protocol, the LD_{50} was found to be over 5000 mg/kg, which classifies CAMEES as practically non-toxic according to standard toxicological guidelines (Firempong *et al.*, 2019; Patel, 2011; Shaw *et al*., 2012).

Sub-chronic toxicity evaluations over a 28-day period reinforced the extract's safety. There were no significant weight losses or deaths, and body weight trends (illustrated in Figures 2 and 3) remained stable across all treatment groups. Although organ weights varied slightly, they didn't show any toxicologically significant changes (see Table 7). A notable increase in lung weight at 250 mg/kg and a decrease at 500 mg/kg ($p < 0.05$) were observed, but without a clear dose-response relationship, indicating these changes may not be biologically meaningful.

The haematological analysis showed that the sub-chronic administration of CAMEES led to some mild changes that were specific to the dose and the sex of the subjects. Notably, there were significant drops in HGB, MCV,

MCH, and MCHC, especially in female rats at a dose of 250 mg/kg. This suggests a trend towards microcytic, hypochromic anaemia. Similar results were noted by Atsamo *et al.*, (2011), who found haematological disruptions, including lower RBC indices, after prolonged administration of *E. senegalensis* extracts in rodents. In our study, we observed a decrease in the red cell distribution width–coefficient of variation (RDW-CV) in males at 500 mg/kg, which might indicate less variability in erythrocyte size, although its clinical significance is likely minimal. Furthermore, the notable drop in the P-LCR across all treated female groups could hint at subtle changes in platelet turnover or structure. These findings align with those of Joshua *et al*., (2020), who reported sex-influenced haematological changes after exposure to methanol leaf extract of *E. senegalensis*, particularly concerning thrombocyte-related parameters. Despite these changes, the values remained within the normal physiological range and did not lead to any mortality or histopathological issues, suggesting that CAMEES, at the doses tested, has a relatively low potential for haematotoxicity. These results are somewhat consistent with Tyohemba, (2019), who found no significant haematological toxicity in rats treated with aqueous extracts of *E. senegalensis* stem bark at doses up to 5000 mg/kg in acute studies. However, the observed sex-specific sensitivity underscores the importance of careful dose consideration and further research, particularly regarding long-term use.

The biochemical parameters also pointed to the extract's somewhat safety. Thus, after administering CAMEES over a sub-chronic period, we noticed some mild changes, especially in liver function and metabolic markers. There was a notable rise in ALT levels at 500 mg/kg, and while AST levels were also elevated, they didn't reach statistical significance, hinting at possible stress on the liver cells (as seen in Table 4). However, since we did not observe any histopathological damage to the liver, it seems these changes might be adaptive or reversible. This finding is in line with Tyohemba, (2019), who found no significant liver damage after giving *E. senegalensis* stem bark extract at doses up to 5000 mg/kg. We also saw a significant increase in serum albumin at 250 and 500 mg/kg, which could suggest that the liver is ramping up protein production, a point previously noted by Udem *et al*., (2010) in their studies on methanolic leaf extracts. When it comes to

renal indices—like urea, creatinine, and electrolytes—everything stayed within normal ranges (Table 5), indicating that the extract doesn't seem to have any nephrotoxic effects. This is consistent with the findings of Atsamo *et al*., (2011), who reported that renal function was preserved in rats treated with polyherbal formulations containing *E. senegalensis*. Interestingly, we found (in Table 6) that blood glucose levels were significantly higher at 500 mg/kg, while in females, there was a decrease at 250 and 1000 mg/kg, suggesting that the effects on glucose metabolism might depend on both the dose and the sex of the subjects. This observation somewhat aligns with Bilanda *et al*., (2020), who noted hypoglycemic tendencies in female rats treated with *E. senegalensis* leaf extract. Additionally, table 6 revealed a significant increase in total cholesterol at 250 mg/kg—particularly in females—hints at an early disruption in lipid metabolism, which could be worth investigating further, although there are no many comparable reports out there. Overall, these results support the relative safety of CAMEES at sub-chronic doses, while also emphasizing the need for more research into its metabolic effects.

It is interesting to note that the lipid profile showed some notable changes. We saw a significant uptick in total cholesterol, reaching 250 mg/kg ($p < 0.05$), and blood glucose levels also increased at 500 mg/kg ($p < 0.05$) (Table 6). While higher cholesterol levels might suggest fat accumulation, they don't necessarily point to toxicity and could be linked to the nutritional aspects of the extract. The rise in glucose levels might just be temporary metabolic effects, but we definitely need more metabolic and endocrine assessments to fully understand what these results mean.

The sub-chronic administration of CAMEES over a 28-day period did not lead to any significant changes in body weight for either male or female rats (see Figures 2 and 3). This suggests that the extract did not negatively impact their appetite, nutrient absorption, or overall metabolism. This finding is consistent with Tyohemba, (2019) and aligns with general toxicological principles, as stable body weight is often seen as a good indicator of systemic tolerability during repeated-dose studies (Olson *et al*., 2000; Teo *et al*., 2002). However, when we looked at organ weights, we did notice some variations that were specific to the dose and the sex of the rats (refer to Table 7). For instance, female rats showed a significant increase in lung weight at a dose of 250

mg/kg, while male rats experienced a significant decrease in heart weight at doses of 500 and 1000 mg/kg. While these changes could indicate a physiological response or an early adaptive change, the lack of corresponding histopathological lesions (see Figure 4) makes it less likely that there is any cardiopulmonary toxicity involved. Similar temporary changes in organ weights without any related pathology have been observed in toxicity studies with medicinal plants like *Vernonia amygdalina* and *Azadirachta indica* (Akah & Alemji, 2009; Mukinda & Syce, 2007). Importantly, the weights of other crucial organs, such as the liver, kidneys, pancreas, spleen, and reproductive organs, remained stable across all dose levels (see Table 7). These results are in line with previous studies on related Fabaceae species, like *Albizia lebbeck* and *Bauhinia monandra*, where administering the extracts did not lead to any toxicologically significant changes in organ weights (Adedapo *et al*., 2007; Udem *et al*., 2010). Overall, the organ-to-body weight ratios stayed within normal ranges, reinforcing the idea that CAMEES has a favorable safety profile at the concentrations tested.

Histological examination of major organs in male and female rats revealed no visible lesions or structural abnormalities across all treatment groups, including those given the highest dose of CAMEES (1000 mg/kg) (Figure 4). The liver, kidneys, heart, lungs, spleen, testis, and uterus retained normal architecture, with well-preserved cellular organization such as intact hepatocytes, glomeruli, renal tubules, alveolar spaces, and reproductive tissues. These findings suggest no significant organ-specific toxicity at the administered doses and are consistent with earlier reports by Tyohemba, (2019) and Atsamo *et al*., (2011), who observed no major histopathological damage from *E. senegalensis* extracts. The preserved tissue structure aligns with the stable clinical signs, body weight, and most biochemical and haematological parameters, reinforcing the extract's safety profile under sub-chronic conditions.

However, standard light microscopy may not detect subtle or early-stage cellular damage, such as mitochondrial or membrane alterations. Future studies using electron microscopy and molecular techniques like immunohistochemistry are recommended to better understand potential subcellular effects. These findings support previous evidence that *E. senegalensis* has a relatively safe pharmacological profile (Atsamo et al., 2011a; Joshua et al., 2020). Nonetheless,

reported toxicity differences across extract types—such as aqueous, methanol, or chloroform ((Atsamo *et al.*, 2011; Obidah *et al*., 2014.; Udem *et al*., 2010)—highlight the role of extraction methods in determining safety, likely due to phytochemical variation. The seeming lack of toxicity observed here suggests that CAMEES may be a safer candidate for traditional or pharmaceutical use, but long-term, reproductive, and developmental toxicity studies are still needed to fully establish its safety.

Conclusion

The findings from this study indicates that that CAMEES appears to be quite safe for Wistar rats following acute and 28-day sub-chronic oral administration. No mortality, behavioural changes, or clear signs of toxicity were observed. Mild changes in haematological and biochemical parameters, particularly red cell indices, liver enzymes, glucose, and cholesterol, were noted but remained within normal physiological ranges and were not associated with pathological effects. Organ weights, tissue histology, and body weight remained largely unaffected. These results support the somewhat safety of CAMEES at doses up to 1000 mg/kg. However, due to subtle biochemical variations and the limits of light microscopy, further studies including chronic, reproductive, developmental, and ultrastructural evaluations are recommended to confirm its medicinal safety.

Acknowledgment

We appreciate the support by the management of Usmanu Danfodiyo University, Sokoto (UDUS), for facilitating for the release of funds from Tetfund, as well as the technical assistance rendered by laboratory staff of UDUTH

Conflicts of interest

The Authors declare none

Funding

This research was funded by the Tertiary Education Trust Fund (Tetfund), under the National Research Fund (NRF) Grant Award Scheme, with reference TETF/ES/DR&D-CE/NRF2020/SETI/110/VOL.1

Ethics statements

This study received a prior-full consent approval from the Health Research Ethics Committee (HREC) of the Usmanu Danfodiyo University, Sokoto-Nigeria, with reference number: UDUS/UREC/2020/006 dated 20/10/2020

Author contribution

SNM and EHM: study protocol/designed and coordination of the entire project. CJU and IYA: pharmacology, heamatology and biochemical studies. SNM, ML and EHM: extraction, elemental analysis and phytochemical study. AAB and CJU: statistical analysis. AHA, SNM and ML: plant collection, identification and preparation. AM and SNM: Manuscript proof reading.

References

Adedapo, A. A., Omoloye, O. A., & Ohore, O. G. (2007). Studies on the toxicity of an aqueous extract of the leaves of Abrus precatorius in rats. Onderstepoort Journal of Veterinary Research, 74(1), 31–36. https://doi.org/10.4102/ojvr.v74i1.137

Ahmad, P., Abdel Latef, A. A., Abd-Allah, E. F., Hashem, A., Sarwat, M., Anjum, N. A., & Gucel, S. (2016). Calcium and potassium supplementation enhanced growth, osmolyte secondary metabolite production, and enzymatic antioxidant machinery in cadmium-exposed chickpea (Cicer arietinum L.). Frontiers in Plant Science, 7(APR2016), 1–12. https://doi.org/10.3389/fpls.2016.00513

Akah, P., & Alemji, J. (2009). Studies on the effects of Vernonia amygdalina leaf extract and fractions on biochemical and hematological parameters in diabetic rats. Planta Medica, 75(09). https://doi.org/10.1055/s-0029-1234707

Atsamo, A. D., Nguelefack, T. B., Datté, J. Y., & Kamanyi, A. (2011a). Acute and subchronic oral toxicity assessment of the aqueous extract from the stem bark of Erythrina senegalensis DC (Fabaceae) in rodents. Journal of Ethnopharmacology, 134(3), 697–702. https://doi.org/10.1016/j.jep.2011.01.023

Atsamo, A. D., Nguelefack, T. B., Datté, J. Y., & Kamanyi, A. (2011b). Acute and subchronic oral toxicity assessment of the aqueous extract from the stem bark of Erythrina senegalensis DC (Fabaceae) in rodents. Journal of Ethnopharmacology, 134(3), 697–702. https://doi.org/10.1016/j.jep.2011.01.023

Baba, H. S., & Mohammed, M. I. (2021). Determination of Some Essential Metals in Selected Medicinal Plants. ChemSearch Journal 12(1):, 12(1), 15–20.

Bent, S., Goldberg, H., Padula, A., & Avins, A. L. (2005). Spontaneous Bleeding Associated with Ginkgo biloba. 94121, 657–661. https://doi.org/10.1111/j.1525-1497.2005.0121.x

Bilanda, D. C., à Goufani Bidingha, R., Djomeni Dzeufiet, P. D., Fouda, Y. B., Ngapout, R. F., Tcheutchoua, Y., Owona, P. E., Njonte Wouamba, S. C., Tanfack Tatchou, L., Dimo, T., & Kamtchouing, P. (2020). Antihypertensive and antidiabetic activities of Erythrina senegalensis DC (Fabaceae) stem bark aqueous extract on diabetic hypertensive rats. Journal of Ethnopharmacology, 246, 112200. https://doi.org/https://doi.org/10.1016/j.jep.2019.112200

Blench, R., Dendo, M., Road, G., & Kingdom, U. (2007). FOR. 0.

Brown, C. E., Trauth, S. E., Grippo, R. S., Gurley, B. J., & Grippo, A. A. (2012). Combined Effects of Ephedrine-Containing Dietary. October 2014. https://doi.org/10.1089/jcr.2012.0021

Chen, Y., Cheng, C., Tan, H., Tam, C. W., & Wang, N. (2021). Efficacy of Herbal Medicines Intervention for Colorectal Cancer Patients With Gastrointestinal Toxicity — a Systematic Review and. 11(March). https://doi.org/10.3389/fonc.2021.629132

Diallo, M. S., Dial, C. M., Poaty, H., & Faye, O. (2020). Histopathologic Profile of Miscarriages during First Trimester of Pregnancy in Teaching Hospital of Grand Yoff in Dakar (Senegal). 56–65. https://doi.org/10.4236/ojpathology.2020.101006

Doughari, J. H. (2010). Evaluation of antimicrobial potentials of stem bark extracts of Erythrina senegalensis DC. African Journal of Microbiology Research, 4(17), 1836–1841. http://www.academicjournals.org/ajmr

Doughari, J. H. (2020). ISOLATION AND CHARACTERIZATION OF BIOACTIVE COMPOUND FROM Erythrina senegalensis Stem Bark Extract. African Journal of Microbiology Research, 17(4), 1836–1841.

Ene, A., Boşneagă, A., & Georgescu, L. (2010). Determination of heavy metals in soils using XRF technique. Romanian Reports of Physics, 55(7–8), 815–820.

Evans, W. C. (2009). Trease and Evans' Pharmacognosy: Sixteenth Edition. In Trease and Evans' Pharmacognosy: Sixteenth Edition.

Fennell, C. W., Lindsey, K. L., McGaw, L. J., Sparg, S. G., Stafford, G. I., Elgorashi, E. E., Grace, O. M., & van Staden, J. (2004). Assessing African medicinal plants for efficacy and safety: pharmacological screening and toxicology. Journal of Ethnopharmacology, 94(2), 205–217. https://doi.org/https://doi.org/10.1016/j.jep.2004.05.012

Firempong, C., Komlaga, G., Donkor, A. F., Mensah, M. L. K., Anning, A. K., & Dickson, A. R. (2019). Toxicity and Safety Implications of Herbal Medicines Used in Africa (P. Builders (ed.)). IntechOpen. https://doi.org/10.5772/intechopen.72437

Fofana, S., Ouédraogo, M., Esposito, R. C., Ouedraogo, W. P., Delporte, C., Van Antwerpen, P., Mathieu, V., & Guissou, I. P. (2022). Systematic review of potential anticancerous activities of erythrina senegalensis dc (Fabaceae). Plants, 11(1). https://doi.org/10.3390/plants11010019

Gbile, Z. O. (2017). Vernacular Names of Nigerian Plants: (Yoruba) (pp. 1–101).

Gill, L. S. (1992). Ethnomedical Uses of Plants in Nigeria. Uniben Press. https://books.google.com.ng/books?id=Yc64AAAACAAJ

Gupta, N., Yadav, K. K., Kumar, V., & Prasad, S. (2022). Investigation of Heavy Metal Accumulation in Vegetables and Health Risk to Humans From Their Consumption. 10(February), 1–12. https://doi.org/10.3389/fenvs.2022.791052

He, F. J., & MacGregor, G. A. (2008). Beneficial effects of potassium on human health. Physiologia Plantarum, 133(4), 725–735. https://doi.org/10.1111/j.1399-3054.2007.01033.x

Heaney, R. P., Gallagher, J. C., Johnston, C. C., Neer, R., Parfitt, A. M., & Whedon, G. D.

(1982). Calcium nutrition and bone health in the elderly. The American Journal of Clinical Nutrition, 36(5 Suppl), 986–1013. https://doi.org/10.1093/ajcn/36.5.986

Johnson, D. R., Inouye, L. S., Bednar, A. J., Clarke, J. U., Winfield, L. E., Boyd, R. E., Ang, C. Y., & Goss, J. (2009). Tungsten bioavailability and toxicity in sunflowers (Helianthus annuus L.). Land Contamination and Reclamation, 17(1), 141–151. https://doi.org/10.2462/09670513.939

Joshua, P. E., Okoro, I. J., Ekpo, D. E., Okagu, I. U., & Ogugua, V. N. (2020). Methanol extract of Erythrina senegalensis leaves (MEES) ameliorates Plasmodium berghei-ANKA 65-parasitised aberrations in mice. All Life, 13(1), 66–77. https://doi.org/10.1080/26895293.2020.1718777

Jugdaohsingh, R. (2007). Silicon and bone health. The Journal of Nutrition, Health & Aging, 11(2), 99–110.

Lamy, O., & Burckhardt, P. (2014). Calcium revisited: part II calcium supplements and their effects. BoneKEy Reports, 3(OCTOBER), 1–8. https://doi.org/10.1038/bonekey.2014.74

Lee, J., Oh, W. K., Ahn, J. S., Kim, Y. H., Mbafor, J. T., Wandji, J., & Fomum, Z. T. (2009). Prenylisoflavonoids from Erythrina senegalensis as novel HIV-1 protease inhibitors. Planta Medica, 75(3), 268–270. https://doi.org/10.1055/s-0028-1088395

Lemus, R., & Venezia, C. F. (2015a). An update to the toxicological profile for water-soluble and sparingly soluble tungsten substances. Critical Reviews in Toxicology, 45(5), 388–411. https://doi.org/10.3109/10408444.2014.1003422

Lemus, R., & Venezia, C. F. (2015b). An update to the toxicological profile for water-soluble and sparingly soluble tungsten substances. Critical Reviews in Toxicology, 45(5), 388–411. https://doi.org/10.3109/10408444.2014.1003422

Lorke, D. (1983). A new approach to practical acute toxicity testing. Archives of Toxicology, 54(4), 275–287. https://doi.org/10.1007/BF01234480

Medicine, I. of. (2006). Dietary Reference Intakes: The Essential Guide to Nutrient Requirements (J. J. Otten, J. P. Hellwig, & L. D. Meyers (eds.)). The National Academies Press. https://doi.org/10.17226/11537

Moreira, D. de L., Teixeira, S. S., Monteiro, M. H. D., De-Oliveira, A. C. A. X., & Paumgartten, F. J. R. (2014). Traditional use and safety of herbal medicines. Revista Brasileira de Farmacognosia, 24(2), 248–257. https://doi.org/10.1016/J.BJP.2014.03.006

Mukinda, J. T., & Syce, J. A. (2007). Acute and chronic toxicity of the aqueous extract of Artemisia afra in rodents. Journal of Ethnopharmacology, 112(1), 138–144. https://doi.org/10.1016/J.JEP.2007.02.011

Obidah, W., Badung, H. L., Ajuji, J., Peter, H., & Bello, H. (n.d.). Effects of Erythrina senegalensis Aqueous Leaf Extract in Rats. 2(4), 179–185.

Okokon, J. E., Davies, K., John, L., Iwara, K., Li, W. W., & Thomas, P. S. (2022). Phytochemical characterization, antihyperglycaemic and antihyperlipidemic activities of Setaria megaphylla in alloxan-induced diabetic rats. Phytomedicine Plus, 2(1), 100182.

https://doi.org/10.1016/J.PHYPLU.2021.100182

Olson, H., Betton, G., Robinson, D., Thomas, K., Monro, A., Kolaja, G., Lilly, P., Sanders, J., Sipes, G., Bracken, W., Dorato, M., Van Deun, K., Smith, P., Berger, B., & Heller, A. (2000). Concordance of the toxicity of pharmaceuticals in humans and in animals. Regulatory Toxicology and Pharmacology : RTP, 32(1), 56–67. https://doi.org/10.1006/rtph.2000.1399

Patel, P. (2011). Who Guidelines on Quality Control of Herbal Medicines. International Journal of Research in Ayurveda and Pharmacy, 2(4), 1148–1154. http://www.ijrap.net/admin/php/uploads/563_pdf.pdf

Rafferty, K., Davies, K. M., & Heaney, R. P. (2005). Potassium Intake and the Calcium Economy. Journal of the American College of Nutrition, 24(2), 99–106. https://doi.org/10.1080/07315724.2005.10719450

Reid, I. R., Bristow, S. M., & Bolland, M. J. (2015). Calcium supplements: benefits and risks. Journal of Internal Medicine, 278(4), 354–368. https://doi.org/10.1111/joim.12394

Saidu, K., Onah, J., Orisadipe, A., Olusola, A., Wambebe, C., & Gamaniel, K. (2000). Antiplasmodial, analgesic, and anti-inflammatory activities of the aqueous extract of the stem bark of Erythrina senegalensis. Journal of Ethnopharmacology, 71(1–2), 275–280. https://doi.org/10.1016/s0378-8741(00)00188-4

Shah, B. N., & Seth, A. K. (2010). Medicinal Plants as a Source of Anti-Pyretic Agents – A Review. Archives of Applied Science Research, 2(3), 188–195.

Shaw, D., Graeme, L., Pierre, D., Elizabeth, W., & Kelvin, C. (2012). Pharmacovigilance of herbal medicine. Journal of Ethnopharmacology, 140(3), 513–518. https://doi.org/10.1016/j.jep.2012.01.051

Tchacondo, T., Karou, S. D., Batawila, K., Agban, A., Ouro-Bang'na, K., Anani, K. T., Gbeassor, M., & de Souza, C. (2011). Herbal remedies and their adverse effects in Tem tribe traditional medicine in Togo. African Journal of Traditional, Complementary, and Alternative Medicines : AJTCAM / African Networks on Ethnomedicines, 8(1), 45–60. https://doi.org/10.4314/ajtcam.v8i1.60522

Teo, S., Stirling, D., Thomas, S., Hoberman, A., Kiorpes, A., & Khetani, V. (2002). A 90-day oral gavage toxicity study of d-methylphenidate and d,l-methylphenidate in Sprague–Dawley rats. Toxicology, 179(3), 183–196. https://doi.org/https://doi.org/10.1016/S0300-483X(02)00338-4

Tyohemba S.T., Mafulul S. G., 1Memi G. G., 1Ndukwe N. N., Edem U. O., K. W. S. (2019). Protective Effect of Erythrina Senegalensis Stem Bark Extract against Cadmium. Nigerian Research Journal of Chemical Sciences (ISSN: 2682-6054) Vol. 7, Issue 2, 2019. December.

Udem, S. C., Obidoa, O., & Asuzu, I. U. (2010). Acute and chronic toxicity studies of Erythrina senegalensis DC stem bark extract in mice. Comparative Clinical Pathology, 19(3), 275–282. https://doi.org/10.1007/s00580-009-0852-5

Wang, H., Xu, B., Zhang, Y., Duan, Y., Gao, R., He, H., Li, X., & Li, J. (2021). Efficacy and Safety of Traditional Chinese Medicine in Coronavirus Disease 2019 (COVID-19): A Systematic Review and Meta-Analysis.

Frontiers in Pharmacology, 12, 609213. https://doi.org/10.3389/fphar.2021.609213

WHO: Fokunang, C. N., Ndikum, V., Tabi, O. Y., Jiofack, R. B., Ngameni, B., Guedje, N. M., Tembe-Fokunang, E. A., Tomkins, P., Barkwan, S., Kechia, F., Asongalem, E., Ngoupayou, J., Torimiro, N. J., Gonsu, K. H., Sielinou, V., Ngadjui, B., Angwafor, I., Nkongmeneck, A., Abena, O. M., … Kamsu-Kom. (2011). Traditional medicine: Past, present and future research and development prospects and integration in the national health system of Cameroon. African Journal of Traditional, Complementary and Alternative Medicines, 8(3), 284–295. https://doi.org/10.4314/ajtcam.v8i3.65276

Yokel, R. A., & McNamara, P. J. (2001). Aluminium toxicokinetics: an updated minireview. Pharmacology & Toxicology, 88(4), 159–167. https://doi.org/10.1034/j.1600-0773.2001.d01-98.