Isoform-specific modulation of transforming growth factor-βs by *Musa cavendishii* peel extracts attenuates hypertrophic scar formation in a rabbit ear model

Azeez Raji Sheidu*[1], Bilkisu Bello Maiha[2], Mohammed Garba Magaji[1], Tijani Rabiu Giaze[1], Saidi Odoma[2], Ahmed Adebowale Adedeji[1]

[1]Department of Pharmacology and Toxicology, Ahmadu Bello University, Zaria, Nigeria
[2]Department of Pharmacology and Therapeutics, Ahmadu Bello University, Zaria, Nigeria

Submitted: 21st Feb., 2026; Accepted: 25th Feb., 2026; Published online: 30th April., 2026
DOI: https://doi.org/10.54117/jcbr.v6i2.1
**Corresponding Author: Azeez Raji Sheidu; loneumajene4real@yahoo.com*

Abstract

Hypertrophic scarring results from dysregulated wound healing characterized by excessive extracellular matrix deposition, persistent fibroblast activation, and sustained profibrotic signaling. Transforming growth factor-β (TGF-β) isoforms play distinct roles in this process with TGF-β1 and TGF-β2 promote fibrosis, whereas TGF-β3 is associated in regenerative remodeling. Imbalance among these isoforms contributes to abnormal scar maturation. This study evaluated the effects of *Musa cavendishii* peel extracts on hypertrophic scar formation, focusing on isoform-specific TGF-β modulation. Hypertrophic scars were induced in rabbits using the ear excision model. Peel extracts prepared with hexane, ethyl acetate, methanol, and aqueous solvents were applied topically at doses of 375, 750, and 1500 mg/kg under preventive (35-day) and curative (63-day) protocols. Triamcinolone acetonide (40 mg/kg) served as the standard control. Scar tissues were analyzed for TGF-β1, TGF-β2, and TGF-β3 levels using ELISA, and isoform ratios were calculated to assess profibrotic balance supported with histological findings. Extract treatment produced dose- and time-dependent suppression of TGF-β1 and TGF-β2. At 35 days, significant reductions were observed primarily at 1500 mg/kg, while both 750 and 1500 mg/kg were effective after 63 days. High-dose treatment achieved cytokine levels comparable to triamcinolone acetonide. Additionally, extract administration reduced TGF-β1/TGF-β3 and TGF-β2/TGF-β3 ratios, indicating restoration of isoform balance. These findings demonstrate that *Musa cavendishii* peel extracts attenuate hypertrophic scarring through coordinated modulation of TGF-β signaling, supporting their potential as a complementary topical antifibrotic therapy.

Graphical Abstract

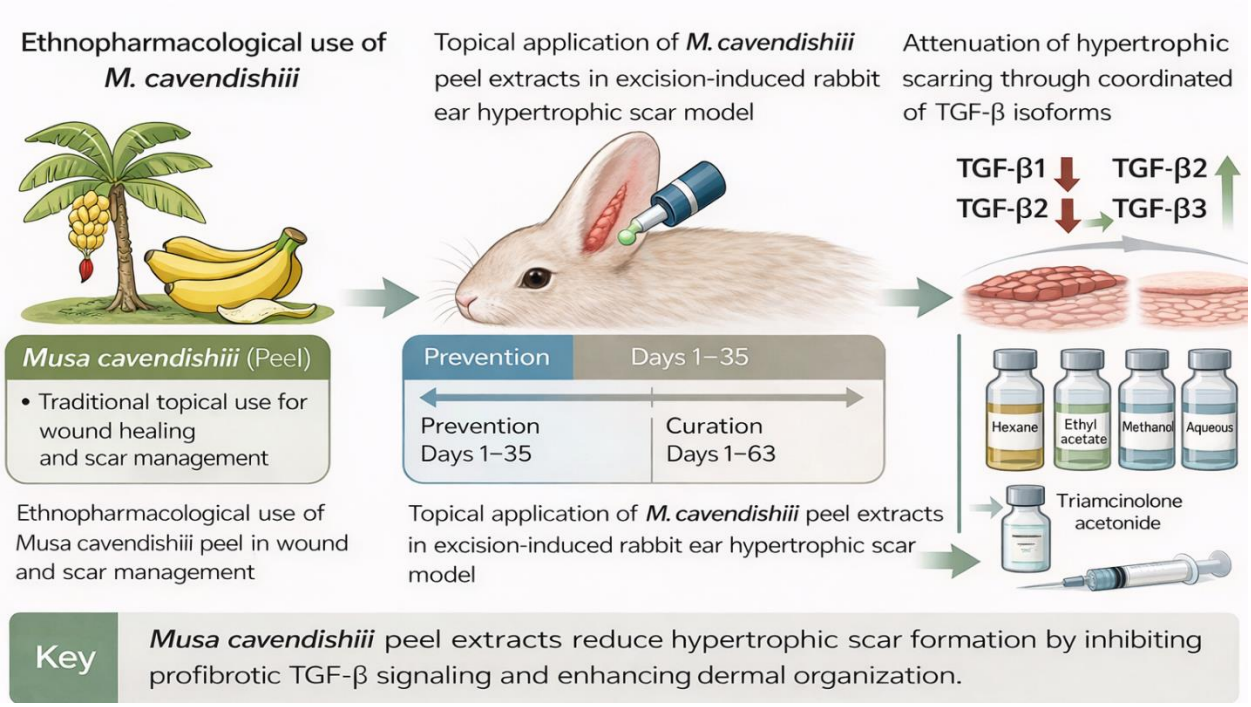

Keywords: Prevention, Curation, Traditional Medicine, Ethnopharmacology, Banana Peel

Introduction

Hypertrophic scarring is a pathological outcome of wound healing characterized by excessive fibroblast activation, abnormal extracellular matrix (ECM) deposition, and impaired tissue remodeling[11,12,19]. Persistent activation of fibrogenic pathways, particularly transforming growth factor-β (TGF-β) signaling, plays a central role in promoting collagen overproduction and sustained scar formation[4,6,19]. Clinically, hypertrophic scars are associated with pain, pruritus, functional limitation, and psychosocial distress, and remain difficult to manage effectively due to high recurrence rates and variable therapeutic responses[8,10]. Despite advances in current therapeutic approaches, including corticosteroid injections and other antifibrotic strategies, treatment outcomes remain inconsistent, highlighting the need for alternative and adjunctive therapies[8,9,20].

Dysregulated transforming growth factor-β (TGF-β) signaling plays a central role in hypertrophic scar pathogenesis[11,12,19]. The three TGF-β isoforms which are TGF-β1, TGF-β2, and TGF-β3 exert distinct but overlapping functions during wound repair and scar formation[6,7,12]. TGF-β1 is the predominant profibrotic isoform, driving fibroblast proliferation, myofibroblast differentiation, angiogenesis, and collagen synthesis; sustained TGF-β1 activation promotes progressive fibrotic scar maturation[4,6,11,19]. TGF-β2 shares significant functional overlap with TGF-β1 and contributes to extracellular matrix accumulation and remodeling, particularly during later phases of wound healing[7,12,21]. In contrast, TGF-β3 has been associated with

improved scar quality and more regulated tissue repair, and growing evidence suggests that the relative balance among TGF-β isoforms rather than absolute cytokine levels alone is a critical determinant of pathological versus regenerative healing outcomes[6,7,12].

Current therapeutic options for hypertrophic scars, including intralesional corticosteroids such as triamcinolone acetonide, provide partial symptomatic improvement but are limited by adverse effects and frequent recurrence[8,10]. These limitations have stimulated interest in alternative antifibrotic strategies capable of targeting key molecular pathways involved in scar formation, particularly TGF-β mediated signaling[4,9,20]. In this context, medicinal plants used in traditional wound care represent valuable sources of bioactive compounds with anti-inflammatory, antioxidant, and tissue-modulating properties[1,3,9].

Musa cavendishii (banana) peel is widely available and has demonstrated wound-healing and anti-scar activities in experimental models[18]. Phytochemical analyses have identified flavonoids, phenolics, terpenoids, saponins, and steroids within the peel[17], many of which are known to influence inflammatory and fibrotic signaling pathways through antioxidant and regulatory mechanisms[1,3]. Previous investigations have reported reductions in collagen accumulation, hydroxyproline content, and inflammatory mediators following treatment with *Musa cavendishii* peel extracts[18]; however, their effects on isoform-specific TGF-β regulation during hypertrophic scar development remain poorly characterized.

The rabbit ear excision model is a well-validated in vivo system that closely replicates the histological and molecular characteristics of human hypertrophic scars[14,2]. Using this model, the present study evaluated the effects of topical *Musa cavendishii* peel extracts under preventive and curative protocols, with emphasis on modulation of TGF-β1, TGF-β2, and TGF-β3 expression. By comparing extract-treated groups with a standard antifibrotic agent, this study sought to determine whether *Musa cavendishii* peel attenuates hypertrophic scarring through coordinated regulation of profibrotic and antifibrotic TGF-β isoforms. Potential sites pathology of TGFβ family members with slight modification is illustrated in the diagram below:

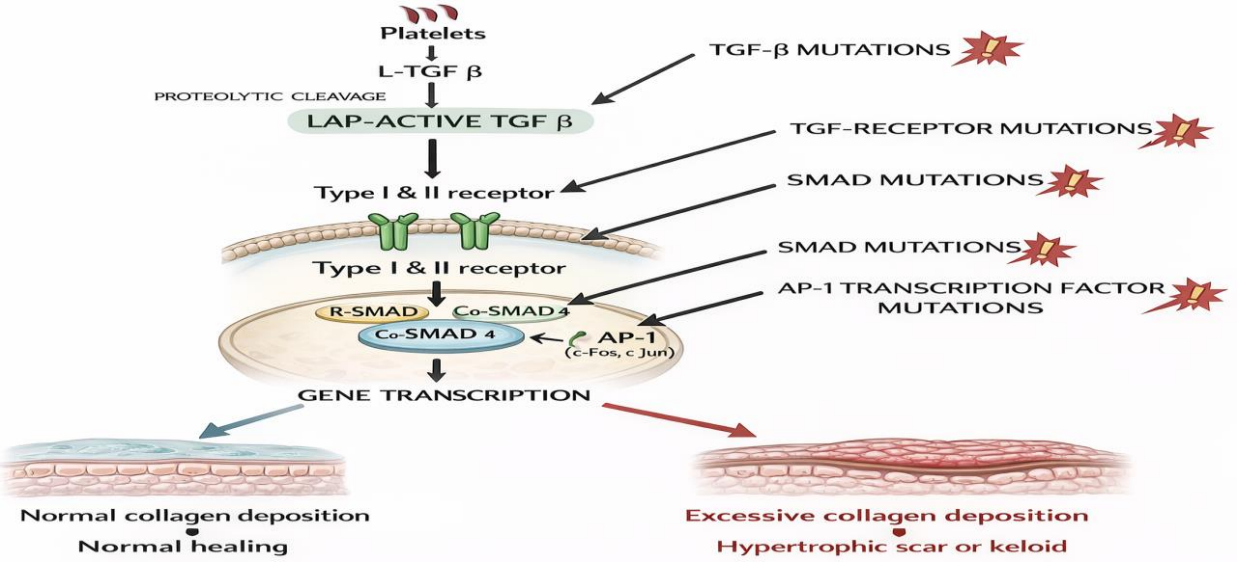

Figure I: Potential sites pathology of TGFβ family members

Keys: TGFβ = Transforming growth factor beta; L-TGFβ, latent TGFβ, LAP = latency associated peptide; R SMAD = receptor regulated SMAD (Similar to Mothers Against Decapentaplegic/Drosophila gene); Co-SMAD = Common partner SMAD; I SMAD = Inhibitory SMAD; SP1 = promoter specific transcription factor 1; AP1-activating protein 1

Materials and Methods

Collection and Authentication of Plant Material

Fresh, mature fruits of *Musa cavendishii* were collected in September from Obehira, Okene Local Government Area, Kogi State, Nigeria (7°33′4.39″ N, 6°14′9.20″ E). The fruits were harvested directly from the plant and transported to the Herbarium Unit, Department of Botany, Faculty of Life Sciences, Ahmadu Bello University, Zaria, Nigeria. Plant identification and authentication were performed by Mallam Namadi Sunusi, and a voucher specimen was prepared and deposited under reference number 28003 for future reference.

Preparation of Plant Material

The peels were manually separated from the fruits, washed to remove adhering debris, and air-dried at room temperature until a constant weight was obtained. The dried peels were then pulverized into coarse powder using a mortar and pestle and stored in clean, airtight containers prior to extraction.

Extraction of *Musa cavendishii* Peel

Extraction of the powdered peel material was carried out using successive maceration with solvents of increasing polarity, following previously described methods with minor modifications. Briefly, 600 g of the powdered sample was macerated in 2,500 mL of n-hexane for 72 h with intermittent agitation. The mixture was filtered using muslin cloth, and the organic solvent extracts (hexane, ethyl acetate, and methanol) were concentrated at room temperature under well-ventilated conditions to allow solvent evaporation. However, the aqueous extract was concentrated using a thermostatically controlled laboratory water bath (SY Series water bath, model BIO-0682) which was used to assist in solvent concentration at of 40-45 °C to facilitate evaporation and prevent microbial contamination or degradation of

heat-labile constituents. All extracts were then labeled appropriately, and stored in a desiccator until use.

Experimental Animals

Forty-two (42) healthy adult New Zealand white rabbits of both sexes, weighing 1.2-2.2 kg, were obtained from the National Animal Production Research Institute (NAPRI), Shika-Zaria, Kaduna State, Nigeria. Animals were housed in the Rabbit Section of the Animal House Facility, Department of Pharmacology and Therapeutics, Ahmadu Bello University, Zaria, under standard laboratory conditions with free access to food and water. Animals were allowed a 14-day acclimatization period prior to experimentation. All procedures involving animals were conducted in accordance with internationally accepted guidelines for laboratory animal care and were approved by the Ahmadu Bello University Committee on Animal Use and Care (ABUCAUC/2018/075).

Experimental Design and Treatment Groups

This study was designed as a randomized, controlled, *in vivo* experimental investigation. Following acclimatization, animals were assigned identification numbers and randomized using a computer-generated random allocation sequence. To minimize potential confounding effects due to biological variability, stratified randomization was performed based on body weight (1.2-1.7 kg and 1.8-2.2 kg) and sex, ensuring balanced distribution across experimental groups. A total of forty-two (42) rabbits were allocated into fourteen (14) groups (n = 3 per group). Group I served as the negative control and received distilled water (1 mL/kg), while Group II served as the positive control and received triamcinolone acetonide (40 mg/kg). Groups III-V received hexane extract of *Musa cavendishii* peel at doses of 375, 750, and 1500 mg/kg, respectively. Groups VI-VIII received ethyl acetate extract at corresponding dose levels (375, 750, and 1500 mg/kg). Groups IX-XI received methanol extract, and Groups XII-XIV received aqueous extract at the same graded doses. Dose selection was guided by preliminary acute dermal toxicity studies and previously published experimental data. All treatments were formulated as topical ointments using a neutral hydrophilic ointment base (petroleum jelly: lanolin, 9:1). Extract concentrations were incorporated to deliver the required mg/kg dose per application area. Triamcinolone acetonide was similarly prepared in the same base to ensure vehicle consistency. The vehicle control group received ointment base alone.

Scar Induction and Dermal Dose Calculation

Hypertrophic scars were induced using the rabbit ear full-thickness excision model. Animals were anesthetized with ketamine (50 mg/kg) and xylazine (3 mg/kg) administered intramuscularly. The ventral surface of each ear was shaved, cleansed, and disinfected with 70% ethanol prior to wounding. Using a sterile biopsy punch template (6 mm diameter), full-thickness dermal excisions were created down to the perichondrium/cartilage layer. Hemostasis was achieved by gentle digital pressure, and wound size uniformity was maintained across all animals (Figure II). For dermal treatment, the required dose (mg/kg) was calculated individually for each animal based on body weight using the formula:

Topical dose per wound (mg) = Body weight (Kg) X Dose (mg/kg)

The calculated quantity of triamcinolone acetonide (40 mg/kg) or extract (375, 750, or 1500 mg/kg) was incorporated into a fixed

amount (0.1 g) of the ointment base to ensure consistent concentration per application. The prepared formulation was then evenly applied directly onto the 6 mm wound surface using a sterile spatula to ensure uniform dermal coverage. Care was taken to confine the application strictly to the wound area to prevent spillage or systemic exposure. Treatments were administered at three-day intervals according to the preventive and curative protocols.



Figure II: Rabbit Ear Excision (1), Scar Evaluation Using Ultrasound (2), Treatment Stages (3a, b, c, d e and f)

Preventive and Curative Treatment Protocols

The left ear was assigned to preventive and right ear to curative protocol for consistency and to avoid procedural confusion during long-term follow-up. However, allocation of treatment groups across animals was randomized. All rabbits used were anesthetized using ketamine (50 mg/kg) and xylazine (3 mg/kg) prior to tissue excision. In the preventive protocol, topical application of test extracts or standard drug commenced immediately after wound excision and continued at three-day intervals for 35 days. The 3-day interval was selected based on rabbit wound healing kinetics (rapid epithelial turnover), prior rabbit ear scar model studies (e.g., Seo et al., 2013) and to mimic repeated clinical topical steroid scheduling. Tissue samples were harvested on day 36. In the curative protocol, excised wounds were left untreated for 1-2 weeks to allow hypertrophic scar formation. Scar development was confirmed by blinded assessment and high-frequency diagnostic ultrasound (Sonostar, China, 12-15 MHz linear probe). Quantified morphometric parameters included scar thickness (mm),

echogenicity pattern and dermal layer uniformity and scar thickness was the primary quantitative endpoint here. Following confirmation, topical treatment was initiated and continued at three-day intervals for a total study duration of 63 days. Hypertrophic scar formation prior to initiation of curative treatment was confirmed using predefined criteria. Scar maturation was assessed by (i) visual and tactile evidence of raised, firm tissue extending beyond the original wound margins; (ii) high-frequency ultrasound measurement demonstrating dermal thickness ≥1.5-fold greater than adjacent normal dermis; and (iii) blinded evaluation by two independent investigators to minimize observer bias. Baseline scar thickness values were recorded prior to commencement of treatment and used as reference points for subsequent therapeutic evaluation. At the end of the experiment, scar tissues were excised for biochemical analysis.

Tissue Processing

Excised scar tissues were rinsed with ice-cold isotonic saline, blotted dry, and homogenized in 0.1 M phosphate buffer (pH 7.4) to obtain 10 % ($^{w}/_{v}$) tissue homogenates. Homogenates were centrifuged at 10,000 rpm for 15 min at 4 °C, and the supernatants were collected and stored at -80 °C until analysis.

Quantification of TGF-β Isoforms

Levels of transforming growth factor-β1 (TGF-β1), TGF-β2, and TGF-β3 in tissue homogenates were quantified using commercially available enzyme-linked immunosorbent assay (ELISA) kits according to the manufacturers' instructions. The ELISA kits for TGF-β1, TGF-β2, and TGF-β3 were obtained from Elabscience Biotechnology Co., Ltd., Wuhan, China. Absorbance was measured at 450 nm using a microplate reader, and cytokine concentrations were determined by extrapolation from standard curves generated for each isoform.

Statistical Analysis

Data were analyzed using SPSS version 23. Results are expressed as mean ± standard error of the mean (SEM). Statistical comparisons among groups were performed using one-way analysis of variance (ANOVA), followed by Bonferroni post hoc multiple comparison tests. A p-value < 0.05 was considered statistically significant.

Results

Effect of *Musa cavendishii* Peel Extracts on TGF-β1 Levels in Rabbit Ear Scar Tissue

Dermal administration of *Musa cavendishii* peel extracts produced dose- and time-dependent modulation of transforming growth factor-β1 (TGF-β1) levels in rabbit ear scar tissue (Tables 1 and 2). After 35 days of treatment, only the highest dose (1500 mg/kg) of all extract fractions like hexane (HEMC), ethyl acetate (EEMC), methanol (MEMC), and aqueous (AEMC) produced a statistically significant reduction ($p \leq 0.05$) in TGF-β1 levels compared with the distilled water (D/W). At this dose, TGF-β1 levels in the extract-treated groups were comparable to those observed with the standard drug, triamcinolone acetonide (40 mg/kg), with no statistically significant difference between the high-dose extract groups and the standard treatment, TCA. Lower doses (375 and 750 mg/kg) did not produce significant changes relative to the distilled water group at this time point. Triamcinolone acetonide alone significantly reduced TGF-β1 levels compared with the control group, confirming the sensitivity of the experimental model. Following 63 days of dermal administration, a more pronounced inhibitory effect on TGF-

β1 was observed. Extract fractions at doses of 750 and 1500 mg/kg produced significant reductions in TGF-β1 levels compared with the vehicle control, indicating enhanced antifibrotic activity with prolonged treatment duration. The greatest reductions were consistently observed at 1500 mg/kg across all solvent fractions. Importantly, TGF-β1 levels in the high-dose groups remained comparable to those achieved with triamcinolone acetonide, with no statistically significant difference between these groups. Treatment at 375 mg/kg remained largely ineffective. Specifically, high-dose AEMC (1500 mg/kg) significantly reduced TGF-β1 levels compared to the distilled water group and achieved values comparable to triamcinolone acetonide, suggesting a similar antifibrotic efficacy at the highest tested dose. Collectively, these findings demonstrate a clear dose- and duration-dependent suppression of TGF-β1, with maximal modulation observed at 1500 mg/kg and enhanced effects following extended treatment.

Table 1: Effect of *Musa cavendishii* Peel Extracts on TGF-β1 Levels in Rabbit Ear Scar Tissue (Preventive Study)

Treatment mg/kg	Transforming Growth Factor β1
D/W 1 mL/kg	197.65±5.15
TCA 40	163.84±2.62
HEMC 375	223.31±5.28
HEMC 750	194.45±2.00
HEMC 1500	148.57±10.80^{c,*}
EEMC 375	202.56±2.52
EEMC 750	202.56±2.52
EEMC 1500	155.06±6.29^{b,*}
MEMC 375	189.25±0.50
MEMC 750	163.72±3.86
MEMC 1500	153.71±13.10^{b,*}
AEMC 375	196.02±1.50
AEMC 750	175.59±4.31
AEMC 1500	165.62±2.25^{a,*}

Values are expressed as Mean ± SEM (n = 3). Data were analyzed using one-way ANOVA followed by Bonferroni post hoc test. a = $p \leq 0.05$, b = $p \leq 0.01$, c = $p \leq 0.001$ compared with vehicle control (D/W), n = 3
Key: ns = not significant, D/W = Distilled water, TCA = Triamcinolone acetonide, HEMC = Hexane extract of *M. cavendishii*, EEMC = Ethylacetate extract of *M. cavendishii*, MEMC = Methanol extract of *M. cavendishii*, AEMC = Aqueous extract of *M. cavendishii*

Table 2: Effect of *Musa cavendishii* Peel Extracts on TGF-β1 Levels in Rabbit Ear Scar Tissue (Curative Study)

Treatment mg/kg	Transforming Growth Factor β 1
D/W 1 mL/kg	207.85±6.25
TCA 40	190.47±5.35
HEMC 375	205.32±5.55
HEMC 750	177.67±5.60
HEMC 1500	136.34±10.94[b,*]
EEMC 375	205.32±5.80
EEMC 750	177.92±4.74
EEMC 1500	135.06±7.38[c,*]
MEMC 375	213.21±13.46
MEMC 750	177.25±4.34
MEMC 1500	132.14±7.75[a,*]
AEMC 375	204.29±8.51
AEMC 750	176.80±4.62
AEMC 1500	133.04±8.29[a,*]

Values are expressed as Mean ± S.E.M. Data were analyzed using One-way ANOVA followed by Bonferroni post hoc test. [a] = $p \leq 0.05$, [b] = $p \leq 0.01$, [c] = $p \leq 0.001$ as compared with control, * = $p \leq 0.05$ as compared with standard group, n = 3

Key: D/W = Distilled water, TCA = Triamcinolone acetonide, HEMC = Hexane extract of *M. cavendishii*, EEMC = Ethylacetate extract of *M. cavendishii*, MEMC = Methanol extract of *M. cavendishii*, AEMC = Aqueous extract of *M. cavendeshii*

Effect of *Musa cavendishii* Peel Extracts on TGF-β2 Levels in Rabbit Ear Scar Tissue

Dermal administration of *Musa cavendishii* peel extracts also influenced transforming growth factor-β2 (TGF-β2) expression in a dose- and time-dependent manner (Tables 3 and 4). After 35 days of treatment, all extract fractions significantly reduced TGF-β2 levels at the highest dose (1500 mg/kg) when compared with both the control and standard drug groups ($p \leq 0.05$). No statistically significant effects were observed at 375 or 750 mg/kg. These results indicate that short-term suppression of TGF-β2 required higher extract concentrations. In contrast, after 63 days of dermal administration, hexane, methanol, and aqueous extracts produced significant reductions in TGF-β2 levels at both 750 and 1500 mg/kg compared with the control group. Ethyl acetate extract showed a significant effect only at 1500 mg/kg. Notably, none of the extract-treated groups differed significantly from the standard drug at this time point, indicating comparable long-term efficacy between the extracts and triamcinolone acetonide.

Table 3: Effect of *Musa cavendishii* Peel Extracts on TGF-β2 Levels in Rabbit Ear Scar Tissue (Preventive Study)

Treatment mg/kg	Transforming Growth Factor β2
D/W 1 mL/kg	148.10±32.20
TCA 40	111.24±2.98
HEMC 375	149.96±15.97
HEMC 750	108.88±3.97
HEMC 1500	87.22±4.73[a,*]
EEMC 375	153.20±12.80
EEMC 750	108.42±5.82
EEMC 1500	88.18±2.94[a,*]
MEMC 375	145.30±15.66
MEMC 750	107.63±4.52
MEMC 1500	87.34±6.20[a,*]
AEMC 375	157.89±26.19
AEMC 750	109.64±4.37
AEMC 1500	86.98±6.26[a,*]

Values are expressed as Means ± S.E.M. Data were analyzed using One way ANOVA followed by Bonferroni's post hoc test,[a] = $p \leq 0.05$ as compared with the control, [*] = $p \leq 0.05$ as compared with standard, n = 3.
Key: HEMC = Hexane extract of *M. cavendishii*, EEMC = Ethylacetate extract of *M. cavendishii*, MEMC = Methanol extract of *M. cavendishii*, AEMC = Aqueous extract of *M. cavendishii.* TGF=Transforming growth factor

Table 4: Effect of *Musa cavendishii* Peel Extracts on TGF-β2 Levels in Rabbit Ear Scar Tissue (Curative Study)

Treatment mg/kg	Transforming Growth Factor Beta 2
D/W 1 mL/kg	148.62±9.71
TCA 40	93.61±1.82
HEMC 375	141.94±18.71
HEMC 750	106.44±2.80
HEMC 1500	81.87±8.04[a, *]
EEMC 375	137.76±16.60
EEMC 750	109.86±3.77
EEMC 1500	91.17±2.33[a]

MEMC 375	143.92±19.62
MEMC 750	108.40±3.67
MEMC 1500	90.20±2.58[a, *]
AEMC 375	138.42±16.65
AEMC 750	107.14±6.34
AEMC 1500	90.29±1.96[a, *]

Values are expressed as Mean ± S.E.M., Data were analyzed using One-way ANOVA followed by Bonferroni's post hoc test, [a] = $p \leq 0.05$ as compared with the control group, [*] = $p \leq 0.05$ as compared to standard, n = 3.
Key: HEMC = Hexane extract of *M. cavendishii*, EEMC = Ethylacetate extract of *M. cavendishii*, MEMC = Methanol extract of *M. cavendishii*, AEMC = Aqueous extract of *M. cavendishii,* TGF=Transforming growth factor

Effect of *Musa cavendishii* Peel Extracts on TGF-β3 Levels in Rabbit Ear Scar Tissue

Treatment with *Musa cavendishii* peel extracts significantly altered transforming growth factor-β3 (TGF-β3) levels in rabbit ear scar tissue (Tables 5 and 6). After 35 days of dermal administration, all extract fractions produced significant reductions in TGF-β3 levels across the tested doses when compared with the control group ($p \leq 0.05$). No significant differences were observed between extract-treated groups and the standard drug–treated group, indicating comparable short-term suppression of TGF-β3. After 63 days, a clear dose-dependent effect emerged. Extracts administered at 750 and 1500 mg/kg significantly reduced TGF-β3 levels compared with the control group, while treatment at 375 mg/kg remained ineffective. Similar reductions were observed in the standard drug-treated group. The greatest suppression of TGF-β3 was consistently observed at the highest extract dose, suggesting enhanced modulation of antifibrotic signaling with prolonged dermal administration.

Table 5: Effect of *Musa cavendishii* Peel Extracts on TGF-β3 Levels in Rabbit Ear Scar Tissue (Preventive Study)

Treatment mg/kg	Transforming Growth Factor β3
D/W 1 mL/kg	39.21±8.36
TCA 40	17.77±2.42
HEMC 375	29.82±5.84[a]
HEMC 750	15.72±0.81[a]
HEMC 1500	13.90±1.75[a,*]
EEMC 375	29.07±4.32
EEMC 750	15.48±0.91[a]
EEMC 1500	14.46±1.50[a,*]
MEMC 375	27.49±7.45[a]

MEMC 750	16.02±8.36[a]
MEMC 1500	13.97±1.81[a,*]
AEMC 375	28.61±7.60[a]
AEMC 750	16.69±0.70[a]
AEMC 1500	15.65±1.27[a,*]

Values are expressed as Means ± S.E.M., Data were analyzed using One way ANOVA followed by Bonferroni's post hoc test, [a,*] = $p \leq 0.05$ as compared with the control, [*] = $p \leq 0.05$ as compared with standard, n = 3.
Key: HEMC = Hexane extract of *M. cavendishii*, EEMC = Ethylacetate extract of *M. cavendishii*, MEMC = Methanol extract of *M. cavendishii*, AEMC = Aqueous extract of *M. cavendishii.* TGF=Transforming growth factor

Table 6: Effect of *Musa cavendishii* Peel Extracts on TGF-β3 Levels in Rabbit Ear Scar Tissue (Curative Study)

Treatment mg/kg	Transforming Growth Factor β3
D/W 1 mL/kg	25.84±1.23
TCA 40	16.64±1.38
HEMC 375	26.54±1.95
HEMC 750	14.36±0.69[a]
HEMC 1500	13.82±1.37[a,*]
EEMC 375	28.44±3.21
EEMC 750	16.17±0.56[a]
EEMC 1500	15.54±0.69[a,*]
MEMC 375	26.42±3.25
MEMC 750	18.50±1.75
MEMC 1500	14.40±0.08[a,*]
AEMC 375	25.50±2.43
AEMC 750	16.66±0.63[a]
AEMC 1500	15.40±0.47[a,*]

Values are expressed as Means ± S.E.M., Data were analyzed using One-way ANOVA followed by Bonferroni's post hoc test, [a] = $p < 0.05$ as compared with the control, [*] = $p < 0.05$ as compared with standard, n = 3.
Key: HEMC = Hexane extract of *M. cavendishii*, EEMC = Ethylacetate extract of *M. cavendishii*, MEMC = Methanol extract of *M. cavendishii*, AEMC = Aqueous extract of *M. cavendishii.* TGF =Transforming growth factor

Effect of *Musa cavendishii* Peel Extracts on TGF-β Isoform Ratios in Rabbit Ear Hypertrophic Scar Tissue

Table 7.0 presents the effect of *Musa cavendishii* peel extracts on TGF-β isoform balance expressed as TGF-β1/TGF-β3 ratio, TGF-β2/TGF-β3 ratio, and the composite profibrotic index [(TGF-β1+TGF-β2)/TGF-β3] in rabbit ear hypertrophic scar tissue. The distilled water (untreated scar) group demonstrated elevated TGF-β1/TGF-β3 and TGF-β2/TGF-β3 ratios, resulting in a markedly increased profibrotic index. This indicates a dominance of profibrotic isoforms (TGF-β1 and TGF-β2) relative to TGF-β3, consistent with dysregulated remodeling and excessive fibrotic signaling. Treatment with triamcinolone acetonide significantly reduced these ratios compared with the distilled water group ($p \leq 0.05$), reflecting partial normalization of TGF-β isoform balance. Administration of *Musa cavendishii* peel extracts produced dose-dependent modulation of these ratios. At lower doses (375 mg/kg), no significant changes were observed relative to the distilled water serving as control. However, at 750 mg/kg and more prominently at 1500 mg/kg, significant reductions in TGF-β1/TGF-β3 and TGF-β2/TGF-β3 ratios were observed ($p \leq 0.05$). The highest dose (1500 mg/kg) produced ratio values comparable to those of the standard drug group, indicating restoration of isoform equilibrium. Similarly, the composite profibrotic index [(TGF-β1 + TGF-β2)/TGF-β3] was significantly elevated in untreated scars but was markedly reduced following high-dose extract treatment. This reduction suggests coordinated suppression of profibrotic signaling relative to TGF-β3-mediated remodeling activity. Overall, these findings demonstrate that *Musa cavendishii* peel extracts attenuate hypertrophic scarring not merely by reducing absolute cytokine levels, but by rebalancing the relative proportions of TGF-β isoforms. Restoration of this isoform equilibrium is indicative of a shift from excessive fibrosis toward controlled tissue remodeling.

Table 7: Effect of *Musa cavendishii* Peel Extracts on TGF-β Isoform Ratios in Rabbit Ear Hypertrophic Scar Tissue (Curative Study, Day 63)

Treatment (mg/kg)	TGF-β1/TGF-β3	TGF-β2/TGF-β3	(TGF-β1 + TGF-β2)/TGF-β3 (Profibrotic Index)
D/W (Vehicle)	8.05 ± 0.42	5.75 ± 0.31	13.80 ± 0.66
TCA 40	11.45 ± 0.88[a]	5.62 ± 0.44	17.07 ± 1.12[a]
HEMC 375	7.74 ± 0.39	5.35 ± 0.27	13.09 ± 0.58
HEMC 750	12.37 ± 0.71[a]	7.41 ± 0.52[a]	19.78 ± 0.93[a]
HEMC 1500	9.86 ± 0.65[b]	5.92 ± 0.41[b]	15.78 ± 0.88[b]
EEMC 1500	8.69 ± 0.54[b]	5.86 ± 0.37[b]	14.55 ± 0.74[b]
MEMC 1500	9.17 ± 0.48[b]	6.26 ± 0.32[b]	15.43 ± 0.69[b]
AEMC 1500	8.64 ± 0.33[b]	5.86 ± 0.28[b]	14.50 ± 0.51[b]

Values are expressed as Mean ± SEM (n = 3). Data analyzed using one-way ANOVA followed by Bonferroni post hoc test. a = $p \leq 0.05$ vs. vehicle control, b = $p \leq 0.05$ vs. vehicle and not significantly different from TCA

Effect of 63 Days Dermal Administration of *Musa cavendishii* Peel Extracts on the Histology of Rabbit's ear Scar in Skin

Histological examination of scar tissues stained with hematoxylin and eosin (H&E) revealed marked structural differences among experimental groups (Plate I). The distilled water-treated group (D/W 1 mL/kg) demonstrated dense, disorganized collagen bundles with excessive fibroblast proliferation and compact dermal thickening, consistent with hypertrophic scar formation. The dermal architecture appeared distorted with minimal evidence of organized adnexal structures, indicating persistent fibrotic remodeling. In contrast, the triamcinolone acetonide-treated group (TCA 40 mg/kg) showed marked reduction in collagen bundle density with improved dermal organization. Collagen fibers appeared thinner and more uniformly arranged, with reduced fibroblast cellularity, suggestive of attenuated fibrosis and controlled remodeling. Treatment with *Musa cavendishii* peel extracts at 1500 mg/kg demonstrated varying degrees of architectural restoration. The hexane extract (HEMC 1500 mg/kg) exhibited reduced dermal thickening and moderate restoration of organized collagen alignment, with decreased fibroblast proliferation compared to the vehicle group. Similarly, the ethyl acetate extract (EEMC 1500 mg/kg) showed improved dermal structure with reduced inflammatory cell infiltration (LH) and partial re-establishment of glandular and hair follicle structures (GH), indicating progressive remodeling. The methanol extract (MEMC 1500 mg/kg) demonstrated near-normal epidermal continuity and more orderly collagen arrangement, with reduced cellular infiltration relative to untreated scars. The aqueous extract (AEMC 1500 mg/kg) exhibited restoration of dermal architecture with reduced fibrosis and visible normalization of tissue layers, comparable to the standard drug group. Overall, high-dose extract treatment resulted in reduced collagen bundle density, decreased fibroblast proliferation, improved dermal organization, reduced inflammatory infiltration and partial restoration of adnexal structures. These histological findings corroborate the biochemical results demonstrating reduced TGF-β1 and TGF-β2 levels and improved isoform balance. The attenuation of profibrotic cytokine signaling likely contributed to decreased fibroblast activation and controlled extracellular matrix deposition observed microscopically.

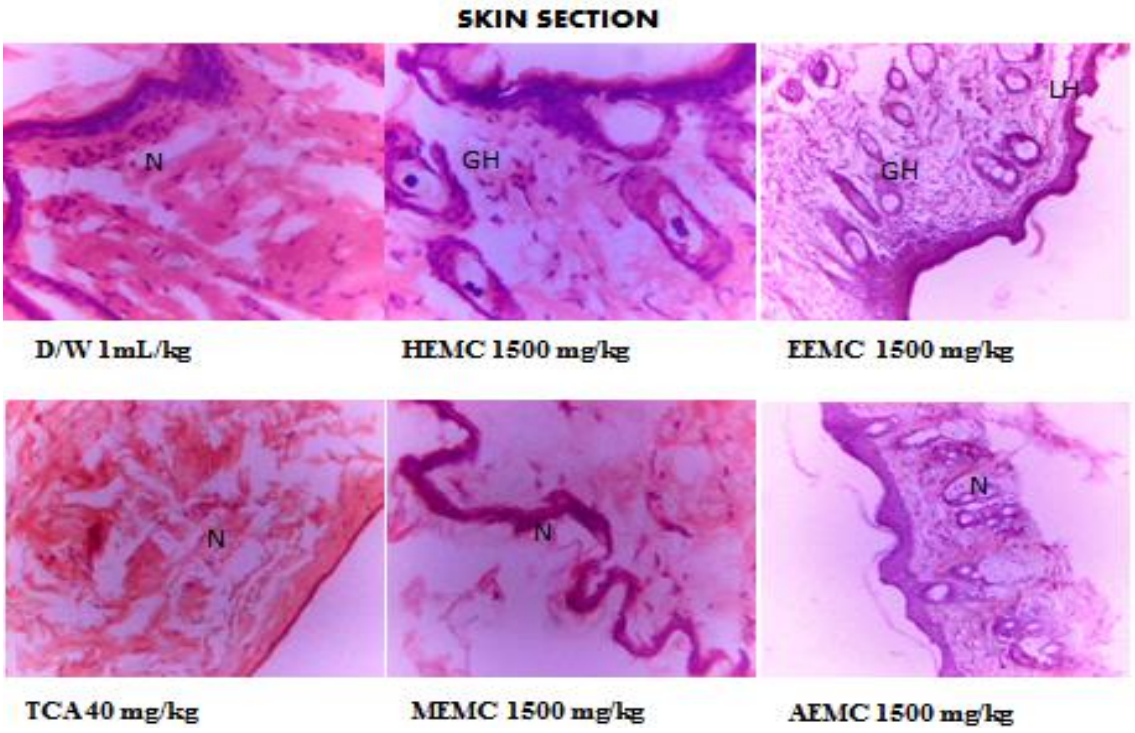

Plate I: **Photomicrograph of the Skin Section for Distilled Water, Standard Drug (TCA), HEMC, EEMC, MEMC and AEMC at 1500 mg/kg after 63 Days Anti-Hypertrophic Scar Study**

Key: GH = Hyperplasia of the glandular cells, LH = Hyperplasia of the inflammatory cells, HEMC = Hexane extract of *M. cavendishii* peel, EEMC = Ethyl acetate of *M. cavendishii* peel, MEMC = Methanol extract of *M. cavendishii* peel, AEMC = Aqueous extract of *M. cavendishii* peel

Table 8: Semi-Quantitative Histological Scoring of Scar Tissue (0-3 scale)

Group	Collagen Density	Fibroblast Proliferation	Inflammatory Infiltration	Dermal Organization
D/W	3	3	2	0
TCA	1	1	1	2
HEMC 1500	1-2	1	1	2
EEMC 1500	1	1	1	2
MEMC 1500	1	1	1	2-3
AEMC 1500	1	1	1	2-3

Scoring criteria: 0 = Normal, 1 = Mild, 2 = Moderate and 3 = Severe

Discussion

Hypertrophic scar formation represents a dysregulated wound healing response characterized by prolonged inflammation, persistent fibroblast activation, excessive myofibroblast differentiation, and exaggerated extracellular matrix (ECM) deposition[11,12,19]. Central to this process is aberrant transforming growth factor-β (TGF-β) signaling, particularly sustained activation of the profibrotic isoforms TGF-β1 and TGF-β2, which promote fibroblast proliferation, α-SMA expression, collagen synthesis, and inhibition of matrix degradation[4,6,11,19]. In contrast, TGF-β3 is generally regarded as

antifibrotic and associated with regenerative healing, and imbalance among TGF-β isoforms is increasingly recognized as a defining molecular feature of pathological scarring[6,7,12].

The present study evaluated the antihypertrophic scar potential of *Musa cavendishii* peel extracts using a validated rabbit ear hypertrophic scar model[2,14], with emphasis on isoform-specific TGF-β modulation and histological correlation. Consistent with established pathophysiology, untreated scars demonstrated elevated TGF-β1 levels, confirming persistent profibrotic signaling within hypertrophic tissue[6,11,19]. Dermal administration of *M. cavendishii* peel extracts produced a clear dose- and time-dependent reduction in TGF-β1 expression. After 35 days, only the highest dose (1500 mg/kg) significantly reduced TGF-β1 compared with vehicle control, whereas both 750 and 1500 mg/kg were effective after 63 days. At the highest dose, TGF-β1 levels were comparable to those achieved with triamcinolone acetonide, suggesting similar antifibrotic activity without statistical superiority. Given the central role of TGF-β1 in fibroblast activation and ECM overproduction[4,6,11], its sustained downregulation provides a mechanistic explanation for the observed antihypertrophic effects.

TGF-β2, which shares overlapping profibrotic functions with TGF-β1[7,12,21], was similarly reduced following extract administration, particularly after prolonged treatment. The greater suppression observed at 63 days aligns with its contribution to later phases of fibrotic remodeling[7,12].

Analysis of TGF-β isoform ratios demonstrated significant reductions in TGF-β1/TGF-β3 and TGF-β2/TGF-β3 ratios, as well as the composite profibrotic index [(TGF-β1 + TGF-β2)/TGF-β3], particularly at 1500 mg/kg. Elevated ratios in untreated scars reflect isoform imbalance favoring fibrosis[6,7,12]. Restoration of isoform equilibrium toward values comparable to triamcinolone acetonide suggests coordinated regulation rather than nonspecific cytokine suppression. Relative predominance of TGF-β3 has been associated with improved collagen organization and reduced scar hypertrophy[6,7,12].

Histological findings corroborated the biochemical results. Vehicle-treated scars exhibited dense, disorganized collagen bundles and increased fibroblast proliferation consistent with hypertrophic pathology[14,19]. Extract-treated groups, particularly at 1500 mg/kg, demonstrated reduced collagen density, improved fiber alignment, and partial restoration of dermal architecture. These effects may be attributed to the phytochemical composition of *M. cavendishii* peel, which contains flavonoids, phenolics, and related antioxidant compounds[17]. Such bioactive constituents are known to modulate inflammatory and fibrotic pathways, including TGF-β/SMAD signaling and oxidative stress responses[1,3,4,9].

Collectively, these findings demonstrate that *M. cavendishii* peel extracts exert dose- and duration-dependent antihypertrophic scar activity through coordinated suppression of TGF-β1 and TGF-β2, restoration of isoform balance, and improvement of dermal architecture. The highest tested dose produced effects

comparable to triamcinolone acetonide, supporting further investigation into the therapeutic potential of *M. cavendishii* peel–derived formulations for hypertrophic scar management.

Conclusion

This study demonstrates that topical *Musa cavendishii* peel extracts effectively attenuate hypertrophic scar formation by modulating profibrotic TGF-β signaling. Dermal application produced dose- and time-dependent suppression of the key fibrogenic isoforms TGF-β1 and TGF-β2, with higher doses and prolonged treatment yielding stronger effects, comparable to those of triamcinolone acetonide. By targeting these central mediators of fibroblast activation, myofibroblast differentiation, and excessive extracellular matrix deposition, the extracts provide a mechanistic basis for scar reduction. These findings highlight *M. cavendishii* peel extracts as a promising, low-cost, plant-based topical therapy for hypertrophic scars and justify further research into their active compounds, safety, and clinical potential.

References

1. Alberts A, Lungescu IA, Niculescu AG, Grumezescu AM. Natural products for improving soft tissue healing: mechanisms, innovations, and clinical potential. *Pharmaceutics*. 2025;17(6):758. doi:10.3390/pharmaceutics17060758
2. Ancuța, D. L., Văduva, M., Coman, C., & Caraș, I. (2026). Recent advances in animal models for pathological scar research: A comprehensive review of experimental approaches and translational relevance. *Animal models and experimental medicine*, *9*(1), 59-71. https://doi.org/10.1002/ame2.70115
3. Baidoo MF, Mensah AY, Ossei PPS, Asante-Kwatia E, Amponsah IK. Wound healing, antimicrobial and antioxidant properties of medicinal plants. *S Afr J Bot*. 2021; 137:52–59. doi: 10.1016/j.sajb.2020.09.037
4. Dimitra E, Alexander O. Targeting TGF-β signaling in fibrosis. *Mol Ther*. 2018;26(4):852–862. doi: 10.1016/j.ymthe.2018.01.009
5. Dogar, A. M., Towbin, H., & Hall, J. (2011). Suppression of latent transforming growth factor (TGF)-beta1 restores growth inhibitory TGF-beta signaling through microRNAs. *The Journal of biological chemistry*, *286*(18), 16447–16458. https://doi.org/10.1074/jbc.M110.208652
6. Finnson KW, McLean S, Di Guglielmo GM, Philip A. Dynamics of transforming growth factor-β signaling in wound healing and scarring. *Adv Wound Care*. 2013; 2(5):195–214. doi:10.1089/wound.2013.0429
7. Gilbert RWD, Vickaryous MK, Viloria-Petit AM. Signaling by transforming growth factor beta isoforms in wound healing and tissue regeneration. *J Dev Biol*. 2016;4(2):21. doi:10.3390/jdb4020021
8. Kazemeini S, et al. Hypertrophic and keloid scar management: advances in diagnosis and therapy. *Cureus*.

2025;17(7): e88810. doi:10.7759/cureus.88810

9. Meetam, T., Angspatt, A., & Aramwit, P. (2024). Evidence of Potential Natural Products for the Management of Hypertrophic Scars. *Journal of evidence-based integrative medicine*, *29*, 2515690X241271948. https://doi.org/10.1177/2515690X241271948

10. Mokos ZB, Jović A, Grgurević L, Dumić-Čule I, Marinović B. Current therapeutic approach to hypertrophic scars. *Front Med*. 2017; 4:83. doi:10.3389/fmed.2017.00083

11. Pakyari M, Farrokhi A, Maharlooei MK, Ghahary A. Critical role of transforming growth factor beta in different phases of wound healing. *Adv Wound Care*. 2013;2(5):215–224. doi:10.1089/wound.2012.0406

12. Penn JW, Grobbelaar AO, Rolfe KJ. The role of the TGF-β family in wound healing, burns and scarring. *Int J Burns Trauma*. 2012;2(1):18–28.

13. Rakoczy, B., Dziedziejko, V., Safranow, K., & Rac, M. (2025). Is TGF-β Associated with Cytokines and Other Biochemical or Clinical Risk Parameters in Early-Onset CAD Patients?. *Biomedicines*, *13*(8), 1840. https://doi.org/10.3390/biomedicines13081840

14. Seo BF, et al. The rabbit ear hypertrophic scar model: reproducibility and molecular characteristics. *Wound Repair Regen*. 2013;21(4):524–533. doi:10.1111/wrr.12062

15. Shalini, T., & Sudhandiran, G. (2025). Provoking myofibroblast death: Strategies to resolve fibrosis and remodel tumor microenvironment. *World journal of clinical oncology*, *16*(12), 111086. https://doi.org/10.5306/wjco.v16.i12.111086

16. Sheidu AR, et al. Antioxidant and Hepatoprotective Potentials of Methanol Extract of Ficus platyphylla stem bark Delile (Moraceae) in Wistar Rats. *Trop J Nat Prod Res.* 2020; 4(3):91-97. doi.org/10.26538/tjnpr/v4i3.6

17. Sheidu AR, Maiha BB, Ahmed A. and Mohammed GM. Successive solvent extraction, phytochemical screening and thin layer chromatography (TLC) profiling of *Musa cavendeshii* linn peel. *Sci Forum (J of pure and applied sci*. 2021; 21 (1): 192. doi.10.5455/SF.103644. Corpus ID: 236696799.

18. Sheidu AR, Maiha BB, Magaji MG, Ahmed A, Giaze TR, Nazifi AB, et al. Anti-hypertrophic scar properties of *Musa cavendeshii* lamb. Peel extracts in New-Zealand rabbit ear wound: The involvement of hydroxyproline and histamine. J of Bio and Phyt. 2024; 3 (2): 26-34. Doi 10.34172/jbp.2024.17

19. Wang XJ, et al. Role of TGF-β signaling in skin fibrosis and pathological scarring. *J Invest Dermatol*. 2006;126(2):245–252. doi: 10.1038/sj.jid.5700056

20. Zhang, Y., Liu, E., Gao, H., He, Q., Chen, A., Pang, Y., Zhang, X., Bai, S., Zeng, J., & Guo, J. (2024). Natural products for the treatment of hypertrophic scars: Preclinical and clinical studies. *Heliyon*, *10*(17), e37059. https://doi.org/10.1016/j.heliyon.2024.e37059

21. Zhu, X., Zeng, B., Wu, C., Chen, Z., Yu, M., & Yang, Y. (2023). Inhibition of TGF-β2-Induced Trabecular Meshwork Fibrosis by Pirfenidone. *Translational vision science & technology*, *12*(11), 21. https://doi.org/10.1167/tvst.12.11.21