Acute and sub-chronic toxicological profile of Musa cavendishii (Musaceae) Lamb peel extracts in New Zealand rabbit

Azeez Raji Sheidu*[1,2], Bello Bilkisu Maiha[2], Mohammed Garba Magaji[2], Ahmed Abubakar[3], Tijani Rabiu Giaze[4], Abdullahi Balarabe Nazifi[5]

[1]FCT College of Nursing Sciences, Gwagwalada, Abuja-Nigeria
[2]Department of Pharmacology and Therapeutics, Ahmadu Bello University, Zaria-Nigeria
[3]Department of Pharmacognosy and Drug Development, Ahmadu Bello University, Zaria- Nigeria
[4]Department of Pharmacology and Toxicology, Faculty of Pharmaceutical Sciences, Usmanu Danfodiyo University, Sokoto
[5]Department of Pharmacology and Therapeutics, Faculty of Pharmaceutical Sciences, Bayero University, Kano

Submitted: 12th August., 2023; Accepted: 21st Sept., 2023; Published online: 31st Oct., 2023
DOI: https://doi.org/10.54117/jcbr.v3i5.3
**Corresponding Author: Azeez Raji Sheidu; loneumajene4real@yahoo.com; +2348035927240, +238186905326*

Abstract

Musa cavendishii (Musaceae) peel is a waste product of human daily consumable fruit used traditionally in the management of ulceration and scar. This study evaluated the acute and sub-chronic dermal toxicity profile of the hexane, ethylacetate, methanol and aqueous extracts of *M. cavendishii* peel in New Zealand rabbits. Acute and sub-chronic toxicity study of the peel extracts were carried out using methods described by Organization of Economic Corporation and Development (OECD). Changes in body and relative organ weight, hematology, serum liver and renal enzyme were investigated. Vital body organs were also processed for histopathology to observe any alteration from normal architecture. No mortality was observed during the acute toxicity with no changes in body and relative organ weight of the organs tested when compared with the control. The aqueous extract (1500 mg/kg) did not cause significant alterations in the histoarchitexture of the skin's epidermis and dermis with biochemical markers of the rabbits showing normal profile during sub-chronic study. However, mild adipocyte infiltration, glandular hyperplasia and distortions in some renal parameters (creatinine and bicarbonate) were seen in the hexane, ethylacetate and methanol extracts portions at the highest dose (1500 mg/kg) after 28 days topical administration. The findings from this study revealed that acute and 28 days dermal administration of *M. cavendishii* peel extracts are non-toxic in rabbits. However, prolonged use of hexane and ethyl acetate extracts at 1500 mg/kg may result in renal and hepatic injury with dermal irritation.

Keywords: *Musa cavendishii,* peel, dermal toxicology, acute, sub-chronic

Introduction

Medicinal plants, since prehistoric times have been used as source of cure to many illnesses and are recognized by World Health Organization (W.H.O) for this purpose (Whitfield *et al*., 2019). The bioactive constituents present in them were suggested to be the source of their therapeutic endowment which were proven to be less harmful when compared to most synthetic drugs, and this also offer a great scope to new drugs discovery (Newman and Cragg, 2020). These bioactive constituents are capable of modulating metabolic processes which have demonstrated characteristic properties such as antioxidant effect, inhibition of receptor activities, inhibition or induction of enzymes and gene expression (Carbonell-Capella *et al*., 2014; Rossignol *et al*., 2019). Despite these beneficial properties, studies have also shown that many of these medicinal plants used in therapeutics can potentially produce harmful effects (Ertekin *et al*., 2005; Atanasov *et al*., 2021) as some of them have been shown to contain toxic compounds (Sindete *et al*., 2021). Thus, not all medicinal plants are safe for therapeutic purpose which, therefore, necessitate the need to assess their toxicological profile so as to ensure both their short and long term safety.

Musa cavendishii Lamb. belongs to the family *Musaceae* and it is grown for varied ethno-medicinal importance as it has nutritional values including high sugars, fibers, vitamins, and minerals as well as low fat content. The leaves and peel that are often thrown away as waste are used traditionally in the management of wounds, burns and scars (Imam and Akter, 2011; Salehi *et al*., 2020).

The peel from this plant is used in many communities especially in "Ebira land" of Kogi-state, Nigeria, in the management of wound, burns, ulcers and scars. It is locally called "*Apara ogede*"in Ebira "*Bayan ayaba"* in Hausa "*Epo ogede" in* Yoruba*, "Kondong"* in Fulfunde *and "Azu uli*" in Igbo. The phytochemical constituents which may be responsible for its medicinal value have been established in a previous work (Sheidu *et al*., 2021). This study therefore, investigated the dermal toxicological profile of *Musa cavendishii* peel extracts (hexane, ethylacetate, methanol and aqueous) in New Zealand rabbits.

Methods

Collection and identification of plant sample

The plant samples were collected in the month of September, 2022 from Obehira, Okene Local Government, Kogi-state, Nigeria (7° 33' 4.39" N, 6° 14' 9.20" E). The plant was identified and authenticated at the Herbarium, Department of Botany, Faculty of Life Sciences, Ahmadu Bello University, Zaria, by Mallam Namadi Sunusi, and a voucher specimen number (VSN: 28003) was obtained.

Sample preparation

The whole bunch of *M. cavendishii* fruit was separated and placed inside an enclosed sac for 3 days for ripening. After ripening, the fruit peels were collected and air-dried in a room (away from direct sunlight) until a constant weight was obtained. The dried peels were size-reduced into coarse powder using pestle and mortar.

Plant extraction

The powdered peels were subjected to successive extraction process by maceration (Abubakar *et al*., 2019) using hexane, ethyl acetate, methanol and aqueous solution. The powdered plant material (600 g) was extracted successively by first mixing it with 2,500 mL of hexane which was divided into two (2) bottles for convenience (each bottle carries 1,250 mL solvent + powdered peel). This procedure was allowed for three (3) days and on the third day, the hexane layer was filtered using a muslin cloth for about 10-15 minutes for complete drainage. The marc was then spread on a card board paper to dry and the hexane filtrate was poured into an evaporating dish exposed to the air which was allowed to dry for another 3 days. The resulting dried marc was put into a jar and the same procedure was repeated to obtain the ethyl acetate, methanol and aqueous extracts.

Experimental animals

One hundred and sixteen (116) young adult New-Zealand rabbits of both sexes weighing 1.2-2.2 kg were obtained from National Animal Production Research Institution (NAPRI), Shika, Kaduna) and housed in the Animal House of the Department of Pharmacology and Therapeutics, Ahmadu Bello University, Zaria. The animals were maintained under ambient environmental conditions and fed with rabbits' pellet and water *ad libitum*. Before commencement of experiment, ethical approval was sorted from the Committee on Animal Use and Care of A.B.U., Zaria (ABUCAUC/2018/075). Also, the experiments were carried out in accordance with the criteria outlined in

the Guide for the Care and Use of Laboratory Animals by the National Institutes of Health (Publication No 80-23, revised 1996).

Skin preparation for dermal toxicity study

The hair from the area of rabbit to be used were removed and the skin of the dorsal thoracic area clipped one after the other using non tooth forceps (CNZhejiang Geyi Medical Instrument Co., Ltd) under general anaesthesia (ketamine, 50 mg/kg and xylazine, 3 mg/kg). This procedure was followed with manual shaving of the dorsal thoracic region of the rabbits using razor blade and scalpel where applicable. Based on Organization of Economic Corporation and Development (OECD) guidelines 402 (for acute dermal toxicity study) and 410 (for sub-chronic dermal toxicity study), respectively, about 10 % of the body surface area at the thoracic region was shaved by placing an X-ray film constructed like rabbit jacket in the specified region for topical drug application of distilled water as control and *M. cavendishii* peel extracts of different doses (375, 750 and 1500 mg/kg).

Acute dermal toxicity study

Acute toxicity study was conducted using OECD 402 (2017) guideline for chemical testing. In this test, 38 rabbits of different sexes were allocated for the study. Eight (8) out of these thirty eight (38) rabbits were divided into two (2) group of four (4) rabbit each. The first four (4) rabbits were administered topically 200 mg/kg each of *M. cavendishii* peel extracts (hexane, ethyl acetate, methanol and aqueous portion). This same procedure was repeated for 2000 mg/kg and all animals were observed for 24 hours. The remaining thirty (30) rabbits were divided into five groups of six (6) rabbits in each of the four extract portion of *M. cavendishii* peel and distilled water (control) treatments. All the rabbit in each sub-grouping were separated in different animal cages. The first group served as control (administered with distilled water, 1 mL/kg), while the second, third, fourth and fifth groups were the treatment groups that were simultaneously administered different extracts (hexane, ethyl acetate, methanol and aqueous portion) of *M. cavendishii* peel at dose 5000 mg/kg topically. The shaved area and the rabbits were observed for 24 hrs with special attention given to the first 6 hrs and then daily for 14 days. The observations include changes in salivation, tremors, convulsions, diarrhoea, lethargy, sleep, coma, and changes in physical

appearance, injury, pain, changes in skin, fur, eyes and mucous membranes. Individual weights of the rabbits were determined weekly, and at the end of the test, surviving animals were weighed and then euthanized by complete exsanguination. Blood samples were withdrawn from the central vein of the rabbit's ear and collected into non-heparinized and ethylene diamine tetra acetic acid (EDTA) containing tubes for both biochemical and hematological analyses respectively. The following organs: liver, spleen, kidney, lungs and skin tissues were harvested, washed, weighed and fixed immediately in 10 % formalin for a period of 24 hrs, dehydrated with alcohol, embedded in paraffin and all were cut into 4-5 µm thick sections and stained with hematoxylin-eosin (H and E) dye for histology.

Sub-chronic dermal toxicity study

Sub-chronic dermal toxicity study was performed according to OECD guideline 410, (OECD, 2018) for testing of chemicals which were selected based on the information from the acute toxicity profile of the extracts. Three dose levels (375, 750 and 1500 mg/kg were used for sub-chronic toxicity study and 78 rabbits of different sexes were randomly divided into five groups of 6 rabbits each. All were separated in different animal cages to avoid cannibalism. The first group served as control (administered distilled water), while the second, third, fourth and fifth groups were simultaneously administered with different extracts (hexane, ethyl acetate, methanol and aqueous portions) of *M. cavendishii* peel (375, 750 and 1500 mg/kg, dermally, respectively) daily for 28 days. During the period of treatment application, the rabbits were observed daily for signs of toxicity while the weights were taken and recorded weekly. The surviving rabbits were euthanized on the 29th day of the experiment following mild ether anesthesia. Blood samples and organs were collected for hematology and biochemical investigations.

Evaluation of organ body weight ratio

After euthanasia, the kidneys, liver, heart, spleen and lung of the rabbits were excised. These organs were trimmed in order to remove other tissues which were then placed on a soaked gauze and weighed (with paired organ weighed together) using weighing balance. The relative organ weight was calculated using the formula below:

$$\text{Relative organ weight (\%)} = \frac{\text{Organ weight (g)}}{\text{Final body weight (g)}} x\ 100$$

Evaluation of biochemical parameters and electrolytes

Blood samples were withdrawn from the central vein of each rabbit in the different groups and collected in serum plain and EDTA coated bottles. The blood samples were centrifuged at 6026.02 rpm for 5 min and then the serum were collected and stored at −20°C. The serum samples were analyzed using an automatic biochemistry analyzer (NOVA BA-3200, India) to determine the levels of alanine transaminase (ALT), aspartate transaminase (AST), alanine phosphatase (ALP), albumin, total protein, creatinine, urea, total bilirubin, direct bilirubin and electrolytes (sodium, potassium, chloride and bicarbonate).

Evaluation of hematological indices

Using method previously described (Pessini *et al*., 2020), blood samples for hematological evaluation was collected into sample bottles containing EDTA. Thereafter, the values of white blood cell (WBC), lymphocytes, granulocytes, hemoglobin, red blood cells (RBC), packed cell volume (PCV) and platelets were estimated using automated hematology analyzer (DxL 800, Beckman Coulter, U.S.A.).

Histopathological assessment

The skin, heart, liver, lung and kidneys samples were fixed in 10 % formalin for 48 hrs. After fixation, the samples were sliced to 0.5 cm thickness and placed in plastic cassettes for dehydration using an automated processor, before embedded in paraffin using the routine paraffin embedding method (Das *et al*., 2015). The tissue samples were then trimmed and sectioned at 4 μm thickness using microtome which was then placed on a microscope slide and then stained with haematoxylin and eosin (H&E). The sections were then examined microscopically for histological changes.

Statistical analysis

Results were expressed as Mean ± Standard Error of Mean (S.E.M). The data obtained were statistically analyzed using Statistical Package for Social Science (SPSS) software Version 23. Differences between means were analyzed using One Way Analysis of Variance (ANOVA) tool followed by Bonferroni's post hoc test. At $p \leq 0.05$, values were considered statistically significant.

Results

Acute Toxicity

The administration of *M. cavendishii* peel extracts at 200, 2000 and 5000 mg/kg to the rabbits produced no changes in the body of the animals but noticeable hair erection and increased locomotion in the treated rabbits within the first hour of administration were observed. However, there were no changes in the skin, eyes and breathing pattern. After 6 h of administration, no signs of toxicity such as changes in skin, fur, eyes, breathing or behavioral pattern was observed. The acute administration of *M. cavendishii* peel extracts (hexane, ethylacetate, methanol and aqueous extracts) did not result to any mortality after 24 h and throughout the 14 days observation period. The dermal median lethal doses (LD_{50}) of all the extracts were thus estimated to be greater than 5000 mg/kg in rabbits.

Body weight of rabbits in acute toxicity study

The acute dermal administration of *M. cavendishii* peel extracts (hexane, ethyl acetate, methanol and aqueous) at 5000 mg/kg did not produce any significant ($p > 0.05$) change in the body weight of the rabbit as seen after days 1, 7 and 14 when compared to the distilled water (control) group. However, there was a significant ($p < 0.05$) increase in body weight of rabbits in the methanol extract group on day 14 when compared with day 1 (Table 1).

Table 1: Effect of Acute Dermal Administration of *Musa cavendishii* Peel Extracts on Body Weight of Rabbits

Treatment (mg/kg)	Body weight (kg)		
	Day 1	Day 7	Day 14
D/W 1 mL/kg	1.80±0.06	1.81±0.05	1.82±0.05
HEMC 5000	1.71±0.01	1.75±0.03	1.76±0.02
EEMC 5000	1.75±0.03	1.75±0.04	1.76±0.03
MEMC 5000	1.73±0.02	1.78±0.02	1.80±0.02*
AEMC 5000	1.74±0.03	1.72±0.01	1.75±0.02

Values are expressed as Mean ± S.E.M; * = $p<0.05$ as compared to Day 1 – Repeated measure ANOVA followed by Bonferroni's post hoc test, n=3 for each group, D/W = Distilled water, HEMC = Hexane extract of *M. cavendishii* peel, EEMC = Ethylacetate extract of *M. cavendishii* peel, MEMC = Methanol extract of *M. cavendishii* peel, AEMC = Aqueous extract of *M. cavendishii* peel

Relative organ weight of rabbits in acute toxicity study

The acute dermal administration of *M. cavendishii* peel extracts at 5000 mg/kg did not produce significant changes in the relative organ weight of kidneys, liver, spleen and heart of the rabbits when compared to the distilled water (control) group (Table 2).

Table 2: Effect of Acute Dermal Administration of *Musa cavendishii* peel Extracts on Relative Organ Weight of Rabbits

Treatment (mg/kg)	Relative Organ Weight (%)			
	Kidneys	Liver	Spleen	Heart
D/W (1 mL/kg)	0.91±0.01	2.05±0.06	0.13±0.01	0.17±0.02
HEMC 5000	0.15±0.01	2.06±0.13	0.09±0.02	0.15±0.01
EEMC 5000	0.15±0.01	1.50±0.01	0.10±0.01	0.15±0.0
MEMC 5000	0.14±0.01	1.64±0.10	0.11±0.01	0.15±0.01
AEMC 5000	0.15±0.01	1.60±0.12	0.10±0.00	0.15±0.01

Values are expressed as Mean ± S.E.M, n=3 for each group, D/W = Distilled water, HEMC = Hexane extract of *M. cavendishii* peel, EEMC = Ethylacetate extract of *M. cavendishii* peel, MEMC = Methanol extract of *M. cavendishii* peel, AEMC = Aqueous extract of *M. cavendishii* peel

Haematological parameters in acute toxicity study

The acute dermal administration of *M. cavendishii* peel extracts (hexane, ethyl acetate, methanol and aqueous) at 5000 mg/kg significantly ($p < 0.05$) decreased the white blood cell (WBC), granulocyte counts and red blood cell (RBC) when compared to control group. However, the lymphocyte counts, hemoglobin (HGB) and packed-cell volume (PCV) were significantly ($p < 0.05$) increase when compared to control group (Table 3).

Table 3: Effect of Acute Dermal Administration of *Musa cavendishii* Peel Extracts on Hematological Parameters of Rabbits

Parameters	Units	Treatment 5000 mg/kg				
		D/W	HEMC	EEMC	MEMC	AEMC
WBC	10^{-3}/UL	7.80±0.06	5.83±0.06[a]	5.77±0.06[a]	5.63±0.06[a]	5.70±0.10[a]
GRAN	%	58.67±0.03	50.03±0.33[a]	50.03±0.03[a]	50.27±0.03[a]	50.03±0.03[a]
LYMPH	%	30.77±0.63	37.67±0.33[a]	38.33±0.33[a]	38.33±0.33[a]	37.67±0.33[a]
PLT	%	0.18±0.00	0.18±0.00	0.18±0.00	0.18±0.00	0.18±0.00
RBC	10^{-6}/UL	5.53±0.03	4.63±0.03[a]	4.63±0.03[a]	4.63±0.03[a]	4.63±0.03[a]
HGB	g/dL	13.13±0.03	15.63±0.03[a]	15.53±0.03[a]	15.53±0.03[a]	15.53±0.03[a]
PCV	%	41.67±0.88	55.00±0.56[a]	55.33±0.33[a]	54.67±0.33[a]	55.33±0.33[a]

Values are expressed as Means ± S.E.M; [a] = $p<0.05$ as compared to D/W group – One way ANOVA followed by Bonferroni's post hoc test, n = 3, WBC=White blood cells, GRAN=Granulocytes, LYMPH = Lymphocytes, PLT= Platelets, HEMC = Hexane extract of *M. cavendishii* peel, EEMC = Ethylacetate extract of *M. cavendishii* peel, MEMC = Methanol extract of *M. cavendishii* peel, AEMC = Aqueous extract of *M. cavendishii* peel

Histological sections of Skin, Liver, Kidney, Spleen and Heart in acute toxicity study

The histology of the skin sections after acute dermal administration of *M. cavendishii* peel extracts (hexane, ethyl acetate, methanol and aqueous) at 5000 mg/kg showed normal epidermis and dermis. The sections of liver after dermal administration of ethyl acetate and methanol extracts of *M. cavendishii* peel showed mild vacuolation and hepatic necrosis respectively. The kidney sections after dermal administration of the ethyl acetate extract showed mild glandular necrosis. However, the spleen and heart sections showed normal features (Figure 1).

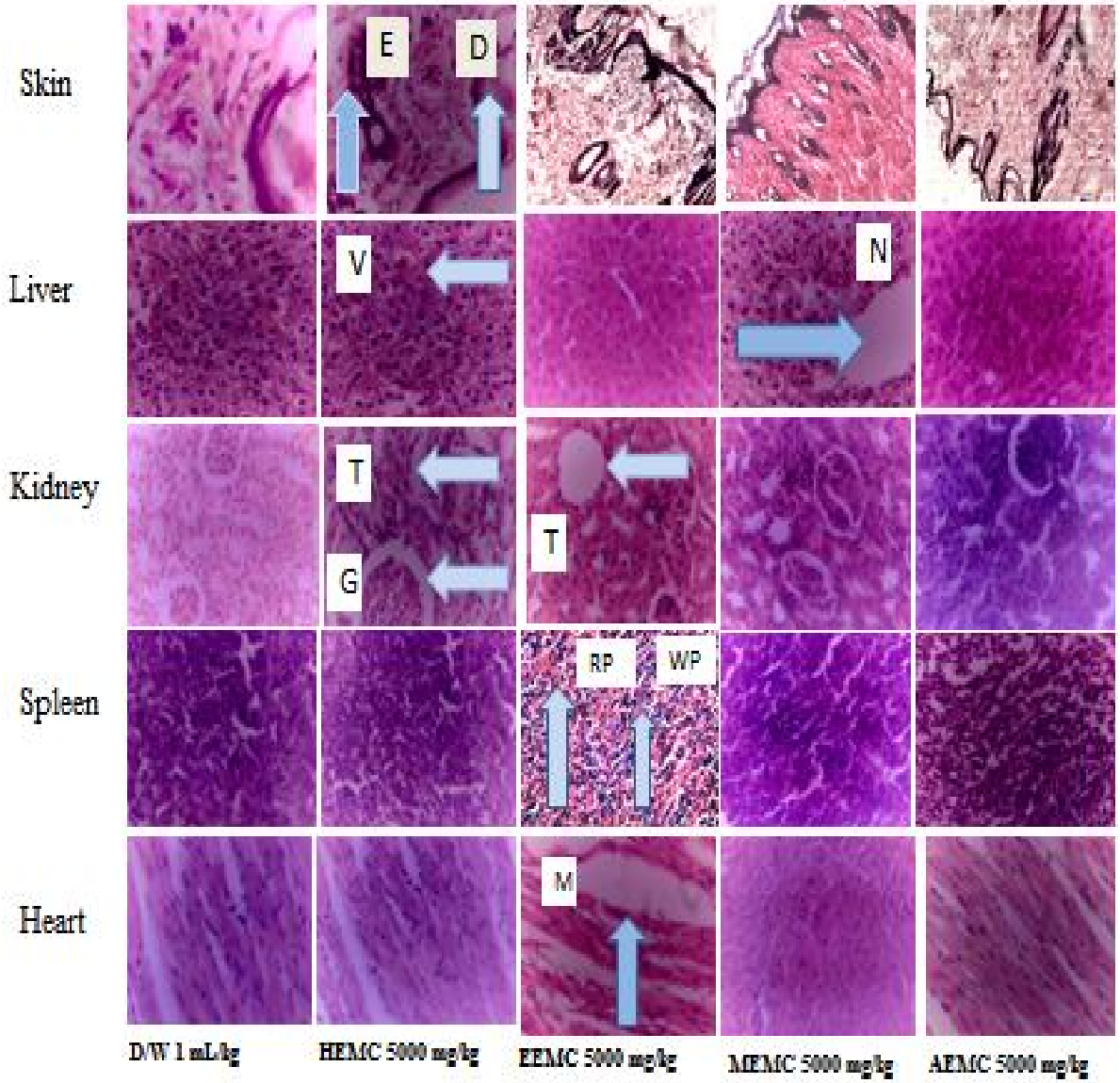

Figure 1: Skin, Liver, Kidney, Spleen and Heart photomicrograph Sections during Acute Dermal Administration of *M. cavendishii* Peel Extracts

Key: HEMC = Hexane extract of *M. cavendishii* peel, EEMC = Ethyl acetate extract of *M. cavendishii* peel, MEMC = Methanol extract of *M. cavendishii* peel, AEMC = Aqueous extract of *M. cavendishii* peel E=Epidermis, D= Dermis, V = Vacuolation, N = Necrosis, T = Tubule, G = Glomerulus, GN = Glomeruli necrosis, RP = Red pulp, WP = White pulp, M = Myocardium (H&E × 400).

Sub-chronic Toxicity Study.

The sub-chronic dermal administration of *M. cavendishii* peel extracts at the tested doses did not produce significant changes in the body and relative organ weight of the animals. There was a significant ($p < 0.05$) increase in serum liver enzyme (ALT and ALP) of hexane extract at dose 1500 mg/kg while the ethyl acetate extract produced a significant ($p < 0.05$) increase in ALT and AST serum liver enzymes and both the methanol and aqueous extracts produced significant ($p < 0.05$) increase serum liver enzyme in ALT. The histology revealed adipocyte infiltration and glandular hyperplasia in the groups administered with extracts of ethyl acetate and methanol at 1500 mg/kg.

Body weight of rabbits in sub-chronic toxicity study

The sub-chronic dermal administration of *M. cavendishii* peel extracts at all the doses tested (375, 750 and 1500 mg/kg) produced no significant changes in the weight of rabbits in all the treatment groups compared to control. However, when compared with day 1, there were significant ($p < 0.05$) increase in the weight of the rabbits at days 14, 21 and 28 (Figure 2).

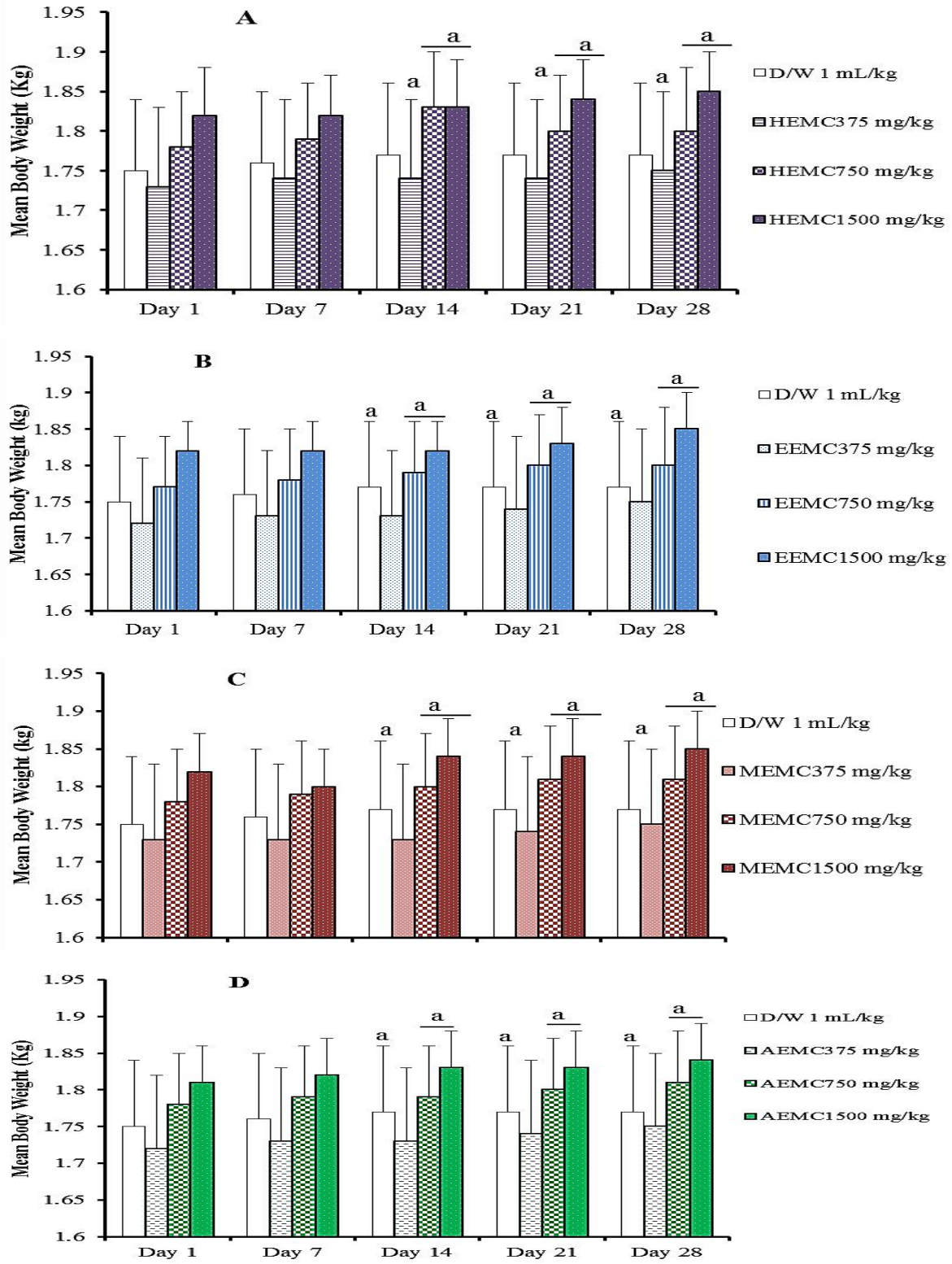

Figure 2: Effect of Sub-Chronic Dermal Administration of *M. cavendishii* Peel Extracts on Body Weight of Rabbits

Values are expressed as Mean ± S.E.M; [a]= $p<0.05$ as compared to Day 1. Data was analyzed using Mixed design ANOVA followed by Bonferroni post hoc test. n=3, D/W = Distilled water, A = HEMC = Hexane extract of *M. cavendishii*, B = EEMC =

Ethylacetate extract of *M. cavendishii*, C = MEMC = Methanol extract of *M. cavendishii*, D = AEMC = Aqueous extract of *M. cavendishii*

Relative organ weight of rabbits in sub-chronic toxicity study

The sub-chronic dermal administration of *M. cavendishii* peel extracts (hexane, methanol and aqueous) at 375, 750 and 1500 mg/kg did not produce significant changes in the relative organ weights of kidneys, liver, heart, spleen and lung (Table 4).

Table 4: Effect of Sub-Chronic Dermal Administration of *M. cavendishii* Peel Extract on Relative Organ Weight of Rabbits

Treatment	Relative Organ Weight (%)				
(mg/kg)	Kidneys	Liver	Heart	Spleen	Lung
D/W (1 mL/kg)	0.43±0.01	2.26±0.10	0.21±0.00	0.03±0.00	0.63±0.13
HEMC 375	0.44±0.01	2.26±0.05	0.20±0.01	0.02±0.00	0.51±0.02
HEMC 750	0.41±0.01	2.23±0.05	0.21±0.00	0.04±0.00	0.54±0.01
HEMC 1500	0.40±0.01	2.15±0.03	0.22±0.01	0.04±0.00	0.84±0.02
EEMC 375	0.43±0.01	2.15±0.05	0.19±0.00	0.02±0.00	0.50±0.01
EEMC 750	0.42±0.01	2.18±0.04	0.19±0.00	0.03±0.00	0.53±0.01
EEMC 1500	0.33±0.03	2.28±0.29	0.25±0.01	0.03±0.01	0.75±0.06
MEMC 375	0.45±0.00	2.43±0.02	0.19±0.00	0.03±0.00	0.47±0.01
MEMC 750	0.42±0.00	2.22±0.01	0.20±0.00	0.04±0.00	0.65±0.01
MEMC 1500	0.27±0.01	1.98±0.07	0.22±0.01	0.03±0.00	0.83±0.02
AEMC 375	0.43±0.00	2.58±0.01	0.19±0.01	0.03±0.00	0.44±0.01
AEMC 750	0.41±0.01	2.23±0.02	0.19±0.00	0.04±0.00	0.59±0.00
AEMC 1500	0.31±0.03	1.79±0.05	0.21±0.01	0.03±0.01	0.74±0.08

Values are expressed as Mean ± S.E.M; n=3, HEMC = Hexane extract of *M. cavendishii* peel, EEMC = Ethylacetate extract of *M. cavendishii* peel, MEMC = Methanol extract of *M. cavendishii* peel, AEMC = Aqueous extract of *M. cavendishii* peel

Serum liver enzyme of rabbits in sub-chronic toxicity study

The sub-chronic dermal administration of hexane extract at all the doses tested (375, 750 and 1500 mg/kg) produced a significant ($p < 0.05$) increase in ALT and ALP. However, the hexane extract at doses 375 and 750 mg/kg produced significant ($p < 0.001$) decrease in AST. The dermal administration of ethyl acetate extract at dose 1500 mg/kg produced significant ($p < 0.001$) increase in ALT and AST. However, all the doses of the ethyl acetate extract tested produced significant ($p < 0.05$) increase in ALP. The 28 days dermal administration of *M. cavendishii* peel methanol extract at dose 1500 mg/kg produced significant ($p < 0.01$) increase in ALT and all the doses tested produced significant ($p < 0.01$) decreased in AST and significant ($p < 0.001$) increase in ALP. The 28 days dermal administration of aqueous extract of *M. cavendishii* peel at dose 1500 mg/kg produced significant ($p < 0.001$) increase in ALT and at doses 375 and 750 mg/kg, the extract produced significant ($p < 0.001$) decrease in AST. However, the aqueous extract at doses 750 and 1500 mg/kg produced significant ($p < 0.001$) increase in ALP (Table 5).

The 28 days dermal administration of *M. cavendishii* peel extracts (hexane, ethyl acetate, methanol and aqueous) at all doses tested produced a significant ($p < 0.05$) increase in TP when compared to control group. At doses of 750 and 1500 mg/kg, the extracts produced a significant ($p < 0.05$) increase in ALB, TB and DB when compared to control group (Table 6).

Table 5: Effect of Sub-Chronic Dermal Administration of *M. cavendishii* Peel Extracts on Serum Liver Enzymes of Rabbits

Treatment (mg/kg)	ALT (IU/L)	AST (IU/L)	ALP (IU/L)
D/W 1 mL/kg	22.33±0.33	12.13±0.09	15.10±0.06
HEMC 375	27.67±0.33[a]	7.50±0.29[c]	18.70±0.06[c]
HEMC 750	29.67±0.33[a]	9.00±0.00[c]	20.17±0.33[c]
HEMC 1500	32.67±0.33[a]	12.07±0.07	23.67±0.03[c]
EEMC 375	21.33±0.33	10.10±0.06	22.10±0.06[c]
EEMC 750	22.33±0.33	12.10±0.06	22.13±0.09[c]

EEMC 1500	26.33±0.33[c]	15.10±0.06[c]	27.10±0.06[c]
MEMC 375	20.33±0.33	5.20±0.12[b]	18.10±0.06[c]
MEMC 750	21.20±0.69	7.77±0.28[b]	19.60±0.29[c]
MEMC 1500	24.50±0.29[b]	10.10±0.06[b]	23.13±0.03[c]
AEMC 375	23.10±0.06	7.10±0.06[c]	14.80±0.06
AEMC 750	22.30±0.06	10.10±0.06[c]	17.17±0.55[c]
AEMC 1500	28.10±0.06[c]	12.10±0.06	19.90±0.06[c]

Values are expressed as Mean ± SEM, [a] = $p<0.05$, [b] = $p<0.01$, [c] = $p<0.001$ as compared to D/W – One way ANOVA followed by Bonferroni's post hoc test, n = 3, ALT= alanine amino transferase, AST = aspartate amino transferase, ALP = alkaline phosphatase, HEMC = Hexane extract of *M. cavendishii*, EEMC = Ethylacetate extract of *M. cavendishii*, MEMC = Methanol extract of *M. cavendishii*, AEMC = Aqueous extract of *M. cavendishii.*

Table 6: Effect of Sub-Chronic Dermal Administration of *M. cavendishii* Peel Extracts on Liver Enzymes of Rabbits

Treatment (mg/kg)	Total protein (g/L)	Albumin (g/L)	Total bilirubin (g/L)	Direct bilirubin (g/L)
D/W 1 mL/kg	3.90±0.06	3.10±0.06	14.13±0.07	5.90±0.06
HEMC 375	4.77±0.03[b]	3.70±0.06	12.67±0.03	6.13±0.03
HEMC 750	7.25±0.03[c]	6.18±0.04[c]	15.15±0.03[c]	8.62±0.04[c]
HEMC 1500	9.73±0.03[a]	8.67±0.03[a]	17.63±0.03[a]	11.10±0.06[a]
EEMC 375	4.53±0.03[b]	3.43±0.03	11.90±0.06	5.10±0.06
EEMC 750	7.05±0.03[c]	5.90±0.00[c]	14.37±0.04[a]	7.60±0.05[c]
EEMC 1500	9.57±0.03[c]	8.37±0.0[c]	16.83±0.03[c]	10.10±0.06[a]
MEMC 375	4.53±0.03[b]	3.23±0.03	13.10±0.06	6.20±0.06
MEMC 750	7.05±0.03[c]	5.70±0.00[c]	15.58±0.04[c]	8.70±0.06[c]
MEMC 1500	9.57±0.03[c]	8.17±0.03[c]	18.07±0.03[c]	11.20±0.06[c]
AEMC 375	4.43±0.03[c]	3.57±0.03	14.67±0.03	6.53±0.03
AEMC 750	6.93±0.03[c]	6.05±0.00 [c]	17.20±0.00[c]	9.08±0.02[c]
AEMC 1500	9.43±0.03[c]	8.53±0.03 [c]	19.73±0.03[c]	11.63±0.03[c]

Values are expressed as Mean ± SEM, [a] = $p<0.05$, [b] = $p<0.01$, [c] = $p<0.001$ as compared to D/W – One way ANOVA followed by Bonferroni's post hoc test, n = 3, D/W = Distilled water, TP= Total protein; ALB = Albumin; TB= Total bilirubin; DB= Direct bilirubin, HEMC = Hexane extract of *M. cavendishii*, EEMC = Ethylacetate extract of *M. cavendishii*, MEMC = Methanol extract of *M. cavendishii*, AEMC = Aqueous extract of *M. cavendishii*

Renal parameters of rabbits in sub-chronic toxicity study

The sub-chronic dermal administration of ethyl acetate extract produced significant ($p < 0.05$) increase in the sodium at all the doses tested, however, the extracts of hexane, methanol and aqueous did not produce any significant ($p > 0.05$) change when compared to control. Considering potassium and creatinine, the sub-chronic dermal administration of the hexane, ethyl acetate, methanol and aqueous extracts at 1500 mg/kg produced a significant ($p < 0.05$) increase when compared to control. However, no significant ($p > 0.05$) change was observed in the chloride following sub-chronic dermal administration of hexane, ethyl acetate and aqueous extracts at the doses tested except for methanol extract (1500 mg/kg) that produced a significant ($p < 0.05$) increase in chloride when compared to control. The sub-chronic dermal administration of hexane, ethyl acetate, methanol and aqueous extracts produced a significant ($p < 0.05$) increase in the bicarbonate at all tested doses when compared to control (Table 7).

Table 7: Effect of Sub-Chronic Administration of *Musa cavendishii* Peel Extracts on Renal Parameter of Rabbits

Treatment (mg/kg)	Urea (g/dL)	Sodium (mmol/L)	Potassium (mg/dL)	Creatinine (mEq/L)	Chloride (mg/dL)	Bicarbonate (mmol/L)
D/W 1 mL/kg	9.90±0.06	89.63±0.06	9.57±0.28	0.82±0.02	26.10±0.06	87.33±0.33
HEMC 375	5.33±0.03	82.60±0.06	9.73±0.03	0.82±0.02	17.17±0.16	110.10±0.06^{c}
HEMC 750	6.80±0.03	85.07±0.04	12.20±0.00^{a}	1.29±0.02^{a}	19.63±0.22	112.58±0.06^{c}
HEMC 1500	8.27±0.03	87.53±0.03	14.67±0.03^{a}	1.77±0.03^{b}	22.30±0.15	115.06±0.07^{c}
EEMC 375	10.67±0.03	105.17±0.03^{a}	8.13±0.03	0.87±0.03	20.13±0.09	105.33±0.33^{c}
EEMC 750	13.17±0.03^{a}	107.65±0.03^{a}	10.63±0.03^{a}	1.36±0.02^{b}	22.62±0.06	107.83±0.33^{c}
EEMC 1500	15.67±0.03^{a}	110.13±0.03^{a}	13.13±0.03^{a}	1.85±0.03^{b}	25.10±0.06	110.33±0.33^{c}
MEMC 375	10.63±0.03	75.10±0.06	8.27±0.03	0.73±0.02	25.10±0.06	99.33±0.33^{c}
MEMC 750	13.10±0.03^{a}	77.58±0.03	10.23±0.03	1.23±0.02^{b}	27.60±0.05	101.83±0.33^{c}
MEMC 1500	15.57±0.03^{a}	80.03±0.03	12.20±0.06^{a}	1.73±0.03^{b}	30.10±0.06^{c}	104.33±0.33^{c}
AEMC 375	9.33±0.03	77.60±0.06	6.43±0.03	0.73±0.02	21.10±0.06	87.33±0.33
AEMC 750	11.82±0.02^{a}	80.08±0.04	8.90±0.00	1.23±0.02^{b}	23.58±0.04	89.83±0.33^{c}
AEMC 1500	14.33±0.03^{a}	82.57±0.03	11.37±0.03^{c}	1.73±0.03^{b}	26.07±0.03	92.33±0.33^{c}

Values are expressed as Mean ± S.E.M., ^{a} = $p<0.05$, ^{b} = $p<0.01$, ^{c} = $p<0.001$ as compared with D/W group – One way ANOVA followed by Bonferroni's post hoc test, n = 3, HEMC = Hexane extract of *M. cavendishii*, EEMC = Ethylacetate extract of *M. cavendishii*, MEMC = Methanol extract of *M. cavendishii*, AEMC = Aqueous extract of *M. cavendishii*

Histological sections of Skin, Liver, Kidneys, Spleen and Heart in sub-chronic Toxicity Study

Photomicrographs of skin, liver, kidneys, and lung and heart sections from rabbits treated with distilled water revealed normal features. Similarly, normal epidermis and dermis of the skin was seen in the aqueous extract and control. However, adipocyte infiltration and glandular hyperplasia were observed in the groups administered with extracts of ethyl acetate and methanol at 1500 mg/kg. The liver section revealed normal architecture in the group administered with ethyl acetate with moderate sinusoidal congestion, vascular congestion and moderate hepatic necrosis in the group administered with ethyl acetate, methanol and aqueous extracts of *M. cavendishii* peel at 1500 mg/kg respectively. All the groups administered with the extracts of *M. cavendishii* peel at 1500 mg/kg showed alveoli congestions in the lung 28 days dermal administration. The sub-chronic dermal administration of *M. cavendishii* peel extracts showed normal myocardium in the heart (Figure 3).

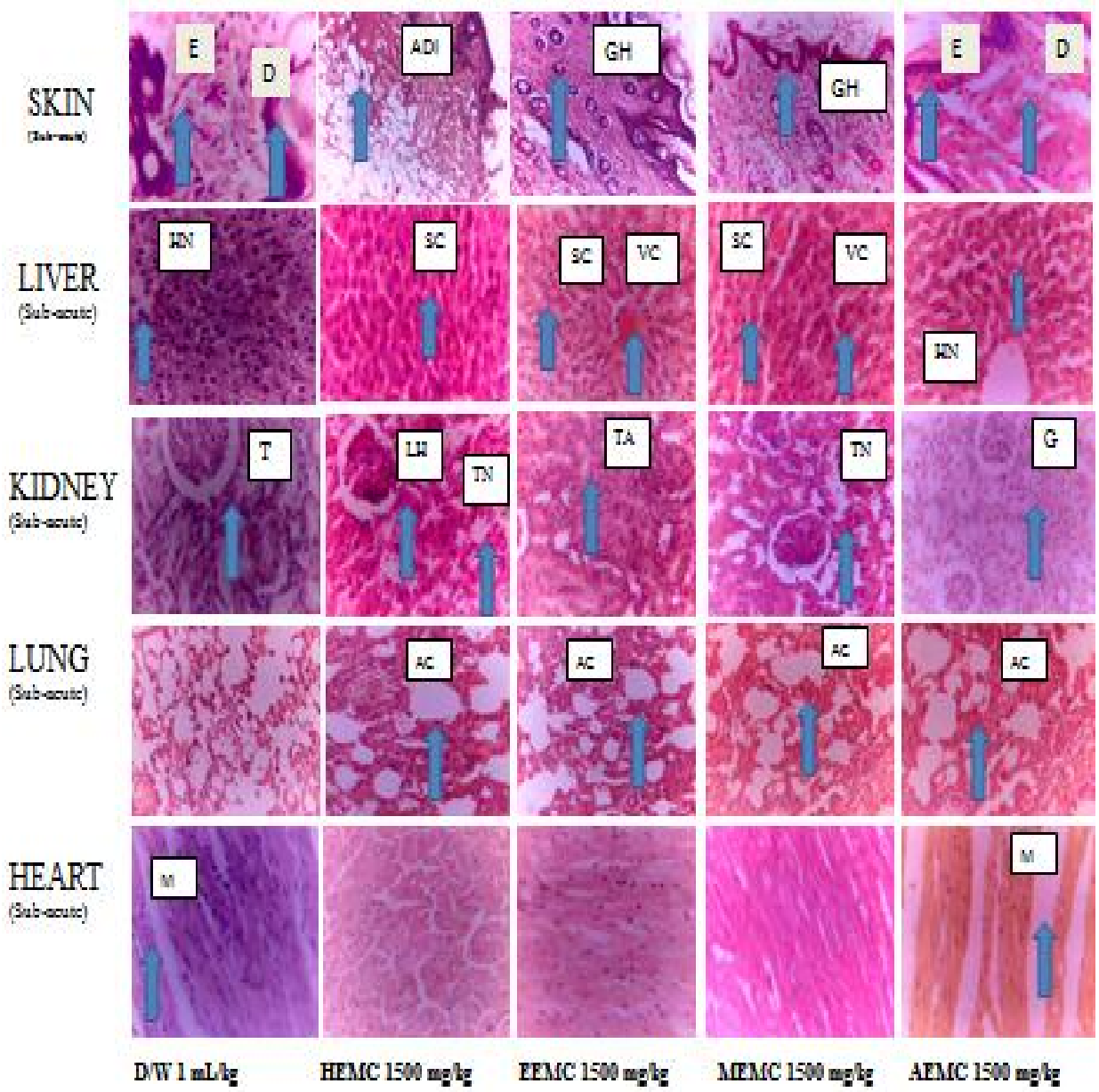

Figure 3: Photomicrograph of Skin, Liver, Kidney and Lung Following Sub-Chronic Dermal Administration of *M. cavendishii* Peel Extracts

Key = Control = Distilled water 1 mL/kg, HEMC = Hexane extract of *M. cavendishii* peel, EEMC = Ethyl acetate extract of *M. cavendishii* peel, MEMC = Methanol extract of *M. cavendishii* peel, AEMC = Aqueous extract of *M. cavendishii* peel ADI = Adipocyte infiltration, GH = Glandular Hyperplasia, E= Epidermis, D= Dermis, SC = Sinusoidal congestion, VC =

Vascular congestion, HN = Hepatic necrosis, T = Tubule, LH = Hyperplasia of inflammatory cells, TN = Tubular necrosis, TA = Tubular adhesion and AC = Alveoli congestion, (H&E × 400)

Discussion

The high demand for the use of medicinal herbs in both human and animal therapeutic management continue to increase daily. Despite the inherent benefits of these medicinal plants, and the perceived safety, available evidence has shown their involvement in the various forms of toxicity (Mensah *et al*., 2019). Determination of the median lethal doses of plant extracts used in traditional medicine through acute toxicity study is of great importance because it provides information regarding the toxicity of such plant. The acute toxicity profile of *M. cavendishii* peel extracts in rabbits showed that their LD_{50} values were greater than 5000 mg/kg body weight. Furthermore, the body and relative organ weights as well as haematological and histological data of the rabbits during acute dermal administration remain unchanged which suggests that *M. cavendishii* peel extracts may be practically non-toxic when administered dermally to the skin (Erb and Kliebenstein, 2020).

Body weight changes, which is visible if body weight reduces by more than 10 % from the starting weight, is often a pointer of unfavorable impacts of medications and chemicals (Deyno *et al*., 2020). The sub-chronic dermal administration of *M. cavendishii* peel extracts did not alter the body weights of the rabbits in all the extracts which implied that the extracts did not have any effect on growth. Also, the relative organ body weight gives vital information relating to physiological and obsessive status in animals which shows whether the organ was presented to damage or not. The extracts of *M. cavendishii* peel did not produce significant change in the relative organ body weights and could, therefore, be considered non-toxic (W.H.O., 2019).

Hepatic functions derangement caused by toxicants could be revealed by investigation of biochemical parameters as liver and kidney play an important role in detoxification (Olorunnisola *et al*., 2012; Angeli *et al*., 2019). ALP, AST and ALT are essential biomarkers of cellular integrity and function of liver and heart, and are often released into blood from damaged liver (Chavda *et al*., 2010). Cellular damage, tissue necrosis and cardiovascular diseases lead to elevation of serum concentrations of ALT and AST (Adeyemi *et al*., 2015). In this study, the administration of different doses of *M. cavendishii* peel extracts significantly reduced the serum levels of ALT and AST which suggested that the extract may not be liable to cause hepatic injury since there were no significant increase in the liver enzymes (Ugbogu *et al*., 2018).

The kidneys play a vital role in the excretion of waste products and toxins such as urea, creatinine and uric acid. They also help in regulation of extracellular fluid volume, serum osmolality and electrolyte concentrations, as well as the production of hormones like erythropoietin and 1, 25 dihydroxy vitamin D and renin (Gounden *et al*., 2022). Among the waste products of kidneys, creatinine and urea remained the most important markers of renal function and are used in diagnoses of kidney diseases or monitor clinical outcome of a therapy (Alomar, 2020). Creatinine is a byproduct of normal muscle function and it is a metabolite of creatinine phosphate which the body use as an energy source and elevation of creatinine level is an indication of impaired kidney function because of poor clearance of creatinine in the blood. In this study, the serum concentration of creatinine was not altered at doses 375 and 750 mg/kg after 28 days dermal administration of *M. cavendishii* peel extracts. Thus *M. cavendishii* peel extracts may be said to maintain the integrity of the renal function parameter. However, at 1500 mg/kg, the toxicological profile of creatinine was raised by ethyl acetate, methanol and aqueous extracts which may be attributed to its prolong use (Gowda *et al*., 2010). Similarly, urea commonly referred to as blood urea nitrogen (BUN) when measured in the blood, is a product of protein metabolism and is considered a non-protein nitrogenous waste product. This is a byproduct of amino acids derived from the breakdown of protein and therefore, the concentration of urea is dependent on protein intake (Jose, 2014). In this study, the urea level was not altered at doses 375 and 750 mg/kg, however, it was increased at dose 1500 mg/kg of both the hexane and ethyl acetate extracts. This showed that the effects of *M. cavendishii* peel extracts on renal function are dose-dependent.

The histological examination of the kidney sections from rabbits treated with different extracts of *M. cavendishii* peel also confirmed the above findings as its dermal administration at higher doses showed slight tubular adhesion, glomerular necrosis and lymphocyte infiltration. This showed that the dermal administration of large doses of *M. cavendishii* peel extracts over 28 days dermal administration might pose a risk to the kidneys (Shadma *et al*., 2021).

Electrolytes are particles that carry an electric charge when they are dissolved in blood and kidneys, maintain these electrolyte concentrations by regulating it in the body to avoid imbalance. The most common

electrolytes associated with the renal failure are potassium, sodium, magnesium, phosphorus and calcium; and their imbalance can further lead to serious complications like bone demineralization, muscle wasting, vascular calcification and death (Pessini *et al*., 2020). Increases or decreases in serum electrolytes level may be caused by a hypo- or hyper-functioning organ or tissue and kidney functions are commonly investigated by assessing the level of sodium, potassium, and chlorides in blood serum (Balogun and Ashafa, 2016). In this study, the sub-chronic dermal administration of *M. cavendishii* peel extracts maintained the level of serum electrolytes in all the doses used (375, 750 and 1500 mg/kg).

Conclusions

The study revealed that acute and 28 days dermal administration of *M. cavendishii* peel extracts are non-toxic in rabbits. However, prolonged use of hexane and ethyl acetate extracts at 1500 mg/kg may result in renal and hepatic injury with dermal irritation.

Conflicts of interest

There are no conflicts of interest regarding this study

Funding

Nil

References

Abubakar, A., Ibrahim, H., Yusuf, K.M., Iliya, I., Suleiman, M.M. and Eloff, N.J. (2019). Antioxidant properties of extracts from *Tacazzea speculate* Oliv.(Periplocaceae) FUW *Trends and Science Technology Journal*, 4 (1): 075-7

Adeyemi, O., Osilesi, O.O., Adebawo, O.D., Onajobi, F., Oyedemi, S. and Afolayan, A. (2015). Alkaline Phosphatase (ALP), Aspartate Aminotransferase (AST) and Alanine Aminotransferase (ALT) Activities in Selected Tissues of Rats Fed on Processed Atlantic Horse Mackerel (*Trachurus trachurus*). *Advances in Bioscience and Biotechnology*, 6, 139-152. doi: 10.4236/abb.2015.63014

Alomar, M.Y. (2020). Physiological and histopathological study on the influence of *Ocimum basilicum* leaves extract on thioacetamide-induced nephrotoxicity in male rats. *Saudi Journal of Biological Science*. 27(7):1843-1849. doi:10.1016/j.sjbs.2020.05.034

Angeli, P., Garcia-Tsao, G., Nadim, M. K. and Parikh, C. R. (2019). News in pathophysiology, definition and classification of hepatorenal syndrome: A step beyond the International Club of Ascites (ICA) consensus document. *Journal of hepatology*, 71(4), 811–822. https://doi.org/10.1016/j.jhep.2019.07.002

Atanasov, A.G., Zotchev, S.B., Dirsch, V.M. and Supuran, C.T. (2021). Natural products in drug discovery: advances and opportunities. *Natural Reviews Drug Discovery,* 20, 200–216. https://doi.org/10.1038/s41573-020-00114-z

Balogun, F. O. and Tom Ashafa, A. O. (2016). Acute and Subchronic Oral Toxicity Evaluation of Aqueous Root Extract of

Dicoma anomala Sond. in Wistar Rats. *Evidence-based complementary and alternative medicine: eCAM*, *2016*, 3509323. https://doi.org/10.1155/2016/3509323

Carbonell-Capella, J. M., Buniowska, M., Barba, F. J., Esteve, M. J., and Frígola, A. (2014). Analytical Methods for Determining Bioavailability and Bioaccessibility of Bioactive Compounds from Fruits and Vegetables: A Review. *Comprehensive reviews in food science and food safety*, 13(2), 155–171. https://doi.org/10.1111/1541-4337.12049

Chavda, R., Valadia, K.R. and Gokani, R. (2010). Hepatoprotective and antioxidant activity of root bark of *Calotropis procera* R. Br (Asclepediaceae). *International Journal of Pharmacology,* 6. https://doi.org/10.3923/ijp.2010.937.943

Das, N., Goshwami, D., Hasan, S. and Raihan, S.Z. (2015). Evaluation of acute and subacute toxicity induced by methanol extract of Terminalia citrine leaves in Sprague Dawley rats. *Journal of Acute Disease*; 4(4): 316-21. https://doi.org/10.1016/j.joad.2015.05.001

Deyno, S., Abebe, A., Tola, M. A., Hymete, A., Bazira, J., Makonnen, E. and Alele, P. E. (2020). Acute and sub-acute toxicity of Echinops kebericho decoction in rats. *BMC Complementary Medicine and Therapies*, 20(1): 2. https://doi.org/10.1186/s12906-019-2794-z

Edenta, C., Okoduwa, S. I. R. and Okpe, O. (2017). Effects of Aqueous Extract of Three Cultivars of Banana (Musa acuminata) Fruit Peel on Kidney and Liver Function Indices in Wistar Rats. *Medicines (Basel, Switzerland)*, *4*(4), 77. https://doi.org/10.3390/medicines4040077

Erb, M. and Kliebenstein, D. J. (2020). Plant Secondary Metabolites as Defenses, Regulators, and Primary Metabolites: The Blurred Functional Trichotomy. *Plant physiology*, *184*(1), 39–52. https://doi.org/10.1104/pp.20.00433

Ertekin, V., Selimoğlu, M. A. and Altinkaynak, S. (2005). A combination of unusual presentations of Datura stramonium intoxication in a child: rhabdomyolysis and fulminant hepatitius. *The Journal of emergency medicine*, *28*(2), 227–228. https://doi.org/10.1016/j.jemermed.2004.11.006

Gounden, V., Bhatt, H. and Jialal, I. Renal Function Tests, (2022). Treasure Island (FL):StatPearls Publishing.

Gowda, S., Desai, P. B., Kulkarni, S. S., Hull, V. V., Math, A. A and Vernekar, S. N. (2010). Markers of renal function tests. *North American journal of medical sciences*, *2*(4), 170–173.

Imam, M. Z and Akter S. *Musa paradisiaca* L. and *Musa sapientum* L: A phytochemical and pharmacological review (2011). *Journal of Applied Pharmaceutical Science*; 1:14–20.

Jose, H. S. (2014). Overview of Urea and Creatinine, *Laboratory Medicine*, 45(1):19–20, https://doi.org/10.1309/LM920SBNZPJRJGUT

Mathew, N.S. and Negi, P.S. (2017). Traditional uses, phytochemistry and pharmacology of wild banana (Musa acuminata Colla): A review. *Journal of Ethnopharmacology,* (196):124–140. doi:10.1016/j.jep.2016.12.009

Mensah, M.L., Komlaga, G., Forkuo, A.D., CalebFirempong, C., Anning, A.K. and Dickson, R.A. (2019). Toxicity and Safety Implications of Herbal Medicines Used in

Africa. In (Ed.), *Herbal Medicine*. doi.org/10.5772/intechopen.72437

Newman, D. J., and Cragg, G. M. (2020). Natural Products as Sources of New Drugs over the Nearly Four Decades from 01/1981 to 09/2019. *Journal of natural products*, *83*(3), 770–803. https://doi.org/10.1021/acs.jnatprod.9b01285.

OECD (2017). Guideline for Testing of Chemicals. Fixed Dose Procedure 14-Days Acute Dermal Toxicity Study in Rodents. Paris, France: Organisation for Economic Co-operation and Development.

OECD (2018). Test No. 410: Repeated Dose Dermal Toxicity: 21/28-day Study, OECD Guidelines for the Testing of Chemicals, Section 4, OECD Publishing, Paris.

Olorunnisola, O. S., Bradley,G and Afolayan, A. J (2012). Acute and sub-chronic toxicity studies of methanolic extract of *Tulbaghia violacea* rhizomes in Wistar rats, *African Journal of Biotechnology* 11(83):14934-14940

Pessini, P. G. D. S., Knox de Souza, P. R., Chagas, C. D. S., Sampaio, E. G., Neves, D. S., Petri, G., Fonseca, F. L. A., and da Silva, E. B. (2020). Hematological reference values and animal welfare parameters of BALB/C-FMABC (*Mus musculus*) inoculated with Ehrlich tumor kept in the vivarium at ABC Medical School. *Animal models and experimental medicine*, 3(1), 32–39. https://doi.org/10.1002/ame2.12099

Rossignol, P., Coats, A. J., Chioncel, O., Spoletini, I., Rosano, G. (2019). Renal function, electrolytes, and congestion monitoring in heart failure [published correction appears in *Eur Heart J Suppl*. 2019 Dec; 21(Suppl M):M72]. *European Heart Journal Supplement*; 21(Suppl M):M25-M31. doi:10.1093/eurheartj/suz220

Salehi, B., Azzini, E., Zucca, P., Maria Varoni, E. V., Anil Kumar, N., Dini, L., Panzarini, E., Rajkovic, J., Valere Tsouh Fokou, P., Peluso, I., Prakash Mishra, A., Nigam, M., El Rayess, Y., El Beyrouthy, M. N., Setzer, W., Polito, L., Iriti, M., Sureda, A., Magdalena Quetglas-Llabrés, M., Martorell, M., Martins, N., Sharifi-Rad, M. M., Estevinho, L. and Sharifi-Rad, J. (2020). Plant-Derived Bioactives and Oxidative Stress-Related Disorders: A Key Trend towards Healthy Aging and Longevity Promotion. *Applied Sciences*; 10(3):947. https://doi.org/10.3390/app10030947

Shadma, A., Sundaram, S and Rai, G. K (2014). Nutraceutical application and value addition of banana peel: A review. *International Journal of Pharmacy and Pharmaceutical Science*; 6:81–5.

Sheidu, A.R., Maiha, B.B., Magaji M.G and Ahmed A (2021). Successive solvent extraction, phytochemical screening, and thin layer chromatography profiling of *Musa cavendishii* Linn peel. *Journal of Pure and Applied Sciences;* 21:192-200. https://doi.org/10.5455/SF.103644

Sindete, M., Gbankoto, A., Osseni, R., Tossavi, N. D., Azonbakin, S., Baba-Moussa, L., and Laleye, A. (2021). A 90-Day Oral Toxicity Study of an Ethanolic Root Extract of *Caesalpinia bonduc* (L.) Roxb. in Wistar Rats. *Evidence-based complementary and alternative medicine: eCAM*, 6620026. https://doi.org/10.1155/2021/6620026

Ugbogu, E. A., Ude, V. C., Elekwa, I., Arunsi, U. O., Uche-Ikonne, C. and Nwakanma, C. (2018). Toxicological profile of the aqueous-fermented extract of *Musa paradisiaca* in rats. *Avicenna journal of phytomedicine*, 8(6):478–487.

Whitfield, J. B., Zhu, G., Madden, P., Montgomery, G. W., Heath, A. C. and Martin, N. G. (2019). Biomarker and Genomic Risk Factors for Liver Function Test Abnormality in Hazardous Drinkers. *Alcoholism, clinical and experimental research*, *43*(3), 473–482. https://doi.org/10.1111/acer.13949

World Health Organization (W.H.O., 2019) global report on traditional and complementary medicine, Geneva, Switzerland.

Zahi, A. K., Hamzah, H., S, H., Shaari, M. R. S., Sithambaram, S. and Othman, H. H. (2015). Acute and Sub-acute Dermal Toxicity Studies of *Morinda citrifolia* L. Fruit Extract in Sprague Dawley Rats. *Asian Journal of Pharmaceutical and Clinical Research*, 8(2): 400–408.